

Case of angioid streaks treated with multiple different anti-vascular endothelial growth factor injection

Abstract

Spider-like irregular, bilateral, dark red to gray lines under the retina which serpent from optic disc to border of posterior pole, are classical clinical findings of angioid streaks (AS). Visual alterations commonly seen in middle-aged patients with AS. Calcified and thickened Bruch membrane breaks are responsible clinical manifestations of AS including retinal pigment epithelial and choriocapillary atrophy, intraretinal/subretinal hemorrhage, pigment epithelial detachment, and choroidal neovascular membrane. Laser photocoagulation, macular translocation surgery, transpupillary thermotherapy, and photodynamic therapy were used to perform in treatment of choroidal neovascular membrane seconder to AS, in past. Today, intravitreal anti-vascular endothelial growth factor injection is the most effective and current treatment method because it provides rapid increments in anatomic and functional results and less aggressive than others. But long-term results and sustainability of first reached positive results are controversial. We presented an AS with visual loss in one eye due to choroidal neovascular membrane and treated with intravitreal aflibercept injection after 5 bevacizumab and 3 ranibizumab injection in a total of 6-year followed-up period while visual acuity of the following eye was stable without any treatment. Although the AS have bilateral disease it has different clinical outcomes due to its asymmetric nature. Even the each anti-vascular endothelial growth factor have some effect on treatment of choroidal neovascular membrane further researches are needed that revealed the treatment protocol and their long-term results in case with AS.

Keywords: angioid streaks, bevacizumab, ranibizumab, aflibercept

Volume 8 Issue 2 - 2018

Ayşe Gul Kocak Altintas,¹ Çağrı İlhan²

¹Associated Professor, University of Health Sciences, Turkey

²Hatay State Hospital, Turkey

Correspondence: Ayşe Gul Kocak Altintas, Associated Professor, University of Health Sciences, Ankara Ulucanlar Eye Education and Research Hospital, Ulucanlar Cad. No: 59 06230 Altındag/Ankara/Turkey, Tel + 90-312-3126261, Fax 90-312-3124827, Email aysegulkaltintas@hotmail.com

Received: March 16, 2018 | **Published:** April 23, 2018

Abbreviations: AS, angioid streaks; RPE, retinal pigment epithelium; OCT, optical coherence tomography; FFA, fundus fluorescein angiography; CNV, choroidal neovascular membrane; PED, pigment epithelial detachment; VEGF, vascular endothelial growth factor; BCVA, best corrected visual acuity; RE, right eye; LE, left eye; IOP, intraocular pressures

Introduction

Doyle was described angioid streaks (AS) in 1889 as spider-like irregular, bilateral, dark red to gray lines under the retina around optic disk.¹ Histopathological studies showed that AS represents breaks and crack-like dehiscences in calcified, thickened both collagenous and elastic part of Bruch membrane. Both atrophy and hyperplasia were developed in retinal pigment epithelium (RPE) and destruction of choriocapillary layers were occurred.² Diagnosis of AS is based on presence of the classical clinical appearance on fundus evaluation and optical coherence tomography (OCT). In fundus fluorescein angiography (FFA) hyperfluorescence were observed over the breaks due to RPE atrophy and hypofluorescence associated with RPE hyperplasia. Complications of AS such as choroidal neovascular membrane (CNV), subretinal hemorrhage and pigment epithelial detachment (PED) may cause legal blindness, especially in middle-aged patients. While, laser photocoagulation, macular translocation surgery, transpupillary thermotherapy and photodynamic therapy were used to applied in treatment of AS patients with visual loss in last decades, intravitreal anti-vascular endothelial growth factor (VEGF)

injection is the most effective and current treatment method for CNV due to AS.³⁻⁷ In this case report, we presented an AS with visual loss in one eye due to CNV which is followed-up 6-year and treated with multiple different anti-VEGF injection. We aimed to show the risk factor of developing CNV in case with AS, the long-term results of different anti-VEGF therapies, the superiority of them from each other and the effectiveness of switch therapy.

Case report

We presented a forty-two year old, Caucasian, male patient with AS without any systemic association who has complained of unilateral visual loss. His best corrected visual acuity (BCVA) was 20/20 in right eye (RE) and 20/30 in left eye (LE). Intraocular pressures (IOP) were bilateral 16 mmHg and slit-lamp anterior segment examinations were completely normal. In both eyes' dilated fundus examination, classical AS appearance was seen in posterior pole, in addition, RPE alterations were observed both eyes while minimal hemorrhages was seen in macular region in LE. In FFA, hypofluorescence in angioid streaks borders and widespread hyperfluorescence the in macular region in both eyes. Figure 1 shows colored fundus images and FFA photographs of both eyes (Figure 1). In OCT, there were hyporeflective spaces in outer retinal layers and hyperreflective band between outer retina and RPE in both eyes. When comparing the findings of two eyes, they were seen that the lesion was parafoveal and fovea relatively spared in right eye and BCVA was 20/20 while the lesion was more subfoveal in left eye and BCVA was decreased.

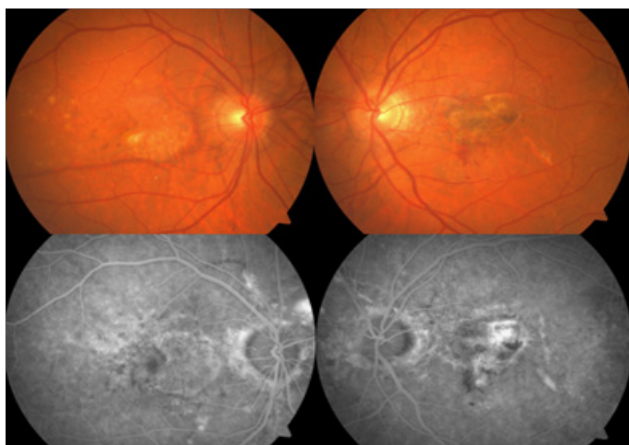


Figure 1 Colored fundus images and fundus fluorescein photographs of both eyes.

Intravitreal anti-VEGF injection was planned for left eye of patient. Repeating intravitreal bevacizumab injections were performed 5-time in 2-year period according to his BCVA, clinical and OCT findings. After the first bevacizumab injection, BCVA increased to 20/25 but 2-month later it suddenly decreased in 20/70 due to submacular

hemorrhage and second intravitreal bevacizumab injection was applied. One month later BCVA increased to 20/25 again. Three months later his BCVA was still 20/25 but he had complained for dysmorphopsia. He had been treating with bevacizumab according to patient's clinical and OCT findings. Patient's functional response of bevacizumab therapy was significantly unstable and subjective symptoms were gradually increased. After 2-year follow-up, even the BCVA was not significantly decreased, due to recurrence of macular fluid and increment of visual symptoms, intravitreal ranibizumab injection was planned. After 3 consecutive ranibizumab injection were performed in one year period, BCVA was remained stable which was 20/30.

One year later, the patient presented with 20/200 BCVA without any trauma. Severe submacular hemorrhage observed on clinically and CNV was found in OCT and FFA evaluations. Hence, intravitreal ranibizumab injection switched to aflibercept therapy. Consecutive 3 injections of aflibercept were performed in one month interval. BCVA was gradually increased to 20/60, submacular hemorrhage was disappeared, macular thickness on OCT due to hemorrhage was disappeared. BCVA was remained as 20/60 even with development of slight lens opacification for one year follow-up after last intravitreal injection. In final OCT, hyporeflective spaces were resolved and legacy outer retinal tubulation was detected which can be seen in natural course of AS (Figure 2).⁸

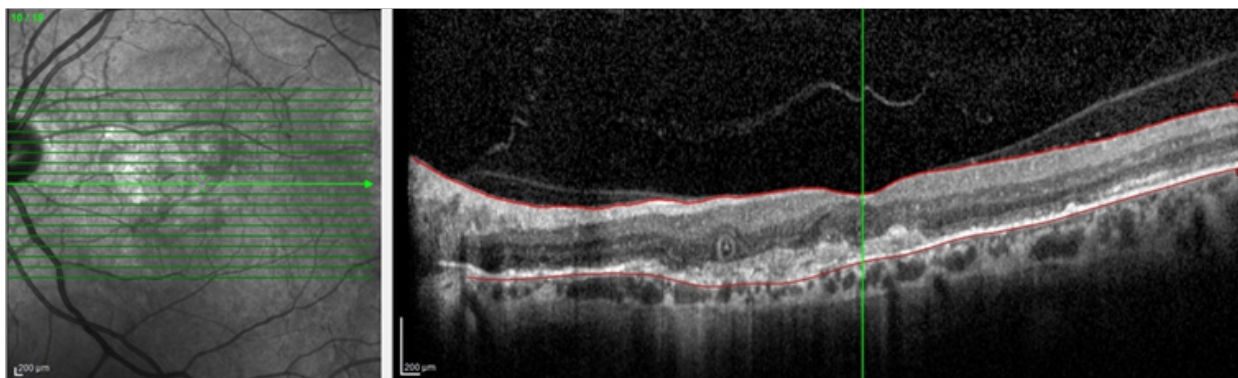


Figure 2 Outer retinal tubulation, resolved hyporeflectivity and increased outer retinal hyperreflectivity in left eye's optical coherence tomography

Discussion

Intravitreal anti-VEGF injection provides the most rapid visual recovery in CNV and the least destructive method for retinal structure. So, in today anti-VEGF therapy is seemed as the first treatment choice in CNV with different etiologies. CNV is responsible the most majority of low vision in cases with AS.⁹ Subfoveal lesions have greater mischance in regard of visual loss. We planned anti-VEGF therapy for left eye of patient because it has subfoveal CNV due to subfoveal breaks in Bruch membrane even the visual acuity was not deeply affected initially, on the other hand, the lesions in right eye was stable during the all follow-up years and visual acuity did not change, where the breaks were occurred parafoveal region.

Alagoz et al.¹⁰ treated 23 eyes with CNV due to AS, with mean 5.1 intravitreal bevacizumab injection in mean 23-month follow-up. They stated that visual acuity was increased or preserved in 65.2% of eyes, however CNV was stable in only 39% eyes in last visit. This article studied the effect of intravitreal bevacizumab injection in AS, has the largest sample size in literature and it shows that relatively

positive and low-sustainable effects of this therapy in medium/long-term.¹⁰ In Lekha et al.¹¹ study showed that recurrence was observed in 73.33% eyes after 5.60 bevacizumab injection over 57.33 months follow-up.¹¹ They concluded that more effective options are needed to reduce risk of recurrence.¹¹ Similarly, we observed sharp changes both significant decrease and increase in patient's visual acuity during the 5 bevacizumab injections in 2.5 years follow-up and first achieved positive anatomic and functional responses could not preserved, patient had complained of severe image distortion.

Tilleul et al.¹² treated 35 eyes of 27 patients with ranibizumab. They stated that end of the 48 months follow-up period, BCVA was improved or stabilized in 62.9% eyes and macular thickness was stabilized or decreased in 45.7% eyes. In addition, no further leakage was observed in 77.1% eyes on FFA at the last visit.¹² They reported that in the light of this values, when compared the effectiveness of bevacizumab and ranibizumab, intravitreal ranibizumab injection seems more effective in long-term results of CNV due to AS. We performed 3 successive intravitreal injection of ranibizumab without need of any other

treatment in following 2 years period after 5 bevacizumab injections in 2.5 years which is the nearly same evaluation period. Visual acuity was stable and complained of dysmorphopsia was totally disappeared and no recurrence was observed both clinically and in OCT findings with the less injections comparing to previous bevacizumab treatment. We observed that effect of IV ranibizumab injection last longer than bevacizumab.

Aflibercept is a new developed anti-VEGF agent that inhibits all isoforms of VEGF-A, VEGF-B and placental growth factor.¹³ Currently there are no any clinical trial in literature investigated the efficacy of aflibercept in CNV secondary to AS and only few cases reported. Esen et al.¹⁴ reported the clinical reports of switching from ranibizumab to aflibercept. After 3 intravitreal aflibercept injections at one month intervals for both of two eyes, visual acuity improved, intraretinal/subretinal fluid resolved, and central macular thickness reduced.¹⁴ We performed successively 3 aflibercept injections as another opinion for our patient after significant decreased in visual acuity due to intensive recently developed submacular hemorrhage with the recurrence of CNV and we reached the favorable anatomic and acceptable functional results without any recurrence. While other eye with the creaks sparing of the fovea was stable in terms of visual acuity in these 6-year period.

Conclusion

AS may occur with significantly asymmetric involvement in each eyes of the same patient. Eyes with creaks of Bruch membrane was located under the fovea has high risk about visual loss due to CNV. Intravitreal anti-VEGF injection is most current treatment modality and even the favorable results are obtained with both ranibizumab and aflibercept, since the underlying etiological factor are persisted recurrence may occur any time. Therefore close follow-up in long term and prompt treatment of patient have high risk of recurrence is essential. At the same time, further researches are needed that revealed the long-term results and treatment regime of each anti-VEGF application in AS.

Acknowledgements

None.

Conflict of interest

The author declares there is no conflict of interest.

References

1. Doyne RW. Choroidal and retinal changes. The result of blows on the eyes. *Trans Ophthalmol Soc UK*. 1889;9:128.
2. Domke H, Tost M. On the histology of "Angioid Streaks". *Klin Monbl Augenheilkd*. 1964;145:18–29.
3. Gliem M, Finger RP, Fimmers R, et al. Treatment of choroidal neovascularization due to angioid streaks: A comprehensive review. *Retina*. 2013;33(7):1300–1314.
4. Gelissen O, Hendrikse F, Deutman AF. A long-term follow-up study of laser coagulation of neovascular membranes in angioid streaks. *Am J Ophthalmol*. 1988;105(3):299–303.
5. Ehlers JP, Maldonado R, Sarin N et al. Treatment of non-age-related macular de- generation submacular diseases with macular translocation surgery. *Retina*. 2011;31(7):1337–1346.
6. Ozdek S, Bozan E, Gürelik G, et al. Transpupillary thermotherapy for the treatment of choroidal neovascularization secondary to angioid streaks. *Can J Ophthalmol*. 2007;42(1):95–100.
7. Lee JM, Nam WH, Kim HK. Photodynamic therapy with verteporfin for choroidal neo- vascularization in patients with angioid streaks. *Korean J Ophthalmol*. 2007;21(3):142–145.
8. Giachetti Filho RG, Zacharias LC, Monteiro TV, et al. Prevalence of outer retinal tubulation in eyes with choroidal neovascularization. *Int J Retina Vitreous*. 2016;2:6.
9. Pece A, Avanza P, Galli L, et al. Laser photocoagulation of choroidal neovascularization in angioid streaks. *Retina*. 1997;17(1):12–16.
10. Alagöz C, Alagöz N, Özkaya A, et al. Intravitreal bevacizumab in the treatment of choroidal neovascular membrane due to angioid streaks. *Retina*. 2015;35(10):2001–2010.
11. Lekha T, Prasad HN, Sarwate RN, et al. Intravitreal Bevacizumab for Choroidal Neovascularization Associated with Angioid Streaks: Long-term Results. *Middle East Afr J Ophthalmol*. 2017;24(3):136–142.
12. Tilleul J, Mimoun G, Querques G, et al. Intravitreal ranibizumab for choroidal neovascularization in angioid streaks: Four-Year Follow-up. *Retina*. 2016;36(3):483–491.
13. Papadopoulos N, Martin J, Ruan Q, et al. Binding and neutralization of vascular endothelial growth factor (VEGF) and related ligands by VEGF Trap ranibizumab and bevacizumab. *Angiogenesis*. 2012;15(2):171–185.
14. Esen E, Sizmaz S, Demircan N. Intravitreal aflibercept for management of subfoveal choroidal neovascularization secondary to angioidstreaks. *Indian J Ophthalmol*. 2015;63(7):616–618.