

Topical bromfenac in the treatment of central serous chorioretinopathy

Abstract

Purpose: To evaluate the effect of topical bromfenac nonsteroidal anti-inflammatory drug (NSAID) in the treatment of acute central serous chorioretinopathy at our facility.

Introduction: CSC is a disorder that is mostly idiopathic, characterized by a serous detachment of the neurosensory retina at the macula, which is caused by active retinal pigment epithelial leakage. Although the exact pathophysiology of CSC has not been clearly elucidated, the primary abnormality leading to RPE disruption and leakage is thought to cause increase choroidal permeability. Studies using different imaging techniques have revealed the possible causes of abnormal permeability of the inner choroid. Ischemia and inflammation might lead to exudative changes within the choroid and the subsequent changes at the RPE. Topical bromfenac, ketorolac, nepafenac and diclofenac all belong to the NSAIDs class of medications. As an anti-inflammatory class, they function by inhibiting the enzyme cyclooxygenase, which blocks the synthesis of prostaglandins. A reduction in prostaglandin formation results a decrease in inflammation. It appears that the principle pathway involved in pain and inflammation is the cyclooxygenase-2 pathway where nonsteroidal anti-inflammatory drugs (NSAIDs) seems to play a significant role.

Material and method: This is an interventional study conducted at Indus Medical College Hospital, Tando Mohammad Khan, from February to September 2017 and includes 11 patients. Patients with acute CSC were included while those with chronic or recurrence were excluded. Careful history taken regarding sensitivity to bromfenac or any other NSAIDs. All patients were diagnosed as having acute CSC relying upon visual acuity by standard Snellen chart, dilated fundus exam using slit lamp with 90D lens and OCT (optical coherence tomography) findings. All patients were treated by bromfenac topical drops twice daily. Patients followed on 5th day, 10th day and 30th day. Vision was recorded, dilated fundoscopy and OCT performed on each visit.

All 11 patients were male (Table 1), divided into 3 age groups i.e. group A(21-30yrs) includes 6(54.54%) patients, group B (31- 40 yrs) includes 4(36.36%) patients and group C (41-50 yrs) includes 1(9.09%) patient (Table 2). 4(36.36%) were right eyes, 7(63.63%)were left (Table 3). Vision recorded using standard Snellen chart, 4(36.36%) patients having vision 0.4, 3 (27.27%) were 0.2, 2 (18.18%) were having 0.1 while remaining 2 (18.18%) were recorded as CF at 1 meter (Table 4). Macular thickness recorded using OCT, patients again divided into 3 groups on OCT findings, group 1, 5(45.45%) patients having macular thickness between 422-485 microns, group 2, 4(36.36%) patients between 535-565 microns while group 3, includes 2(18.18%) patients having

Abbreviations: CSC, central serous chorioretinopathy; NSAIDs, non steroidal anti inflammatory drugs; VEGF, vascular endothelial growth factor; PTD, photodynamic therapy; CFT, central foveal thickness; CME, cystoid macular edema; CF, counting finger; RPE, retinal pigment epithelium

Introduction

Central serous chorioretinopathy (CSC) is an idiopathic disorder characterized by a serous detachment of the neurosensory retina at the macula,¹ which is caused by active retinal pigment epithelial

Volume 7 Issue 7 - 2017

Nisar Ahmed Khan, Atiq Khan, Sobia Khan, Aisha Khan, Aftab Ahmed Khan

Assistant Professor/Consultant, Indus Medical College Hospital, Pakistan

Correspondence: Nisar Ahmed Khan, Assistant Professor/Consultant, Indus Medical College Hospital, Pakistan, Tel +92-300-3014168, Email nisargh2001@yahoo.com

Received: November 13, 2017 | **Published:** December 08, 2017

thickness between 612-644 microns (Table 5). All 11 patients received topical bromfenac, one drop twice daily to treat acute CSC for 10 days and monitor for 1 month.

Results: This is an interventional study includes 11 patients who were diagnosed with acute CSC and followed from the day of presentation to 30th day. All 11 patients were underwent intervention by using topical bromfenac eye drop, one drop twice daily for up to 30th day. Macular thickness and visual acuity recorded from the day of onset up to 30th day.

In group 1, the macular thickness (CFT) improve from 422-485 microns at onset to 317-382 microns on 5th day becomes 246-295 on 10 day while 210-226 on 30th day. Vision improved from 0.4 to 0.7 at 5th day, improved to 0.8 on 10th day and remained same on 30th day. In group 2, the CFT reduced from 535-565 microns at onset to 401-440 microns on 5th day becomes 318-310 on 10th day and on 30th day it was 221-232 microns with improvement in visual acuity which was 0.2 at onset to 0.6 at 5th day, 0.7 on 10th day and improved to 0.8 on 30th day. In group 3 the CFT reduced from 612-644 microns at onset to 560-595 microns on 5th day, 366-388microns on 10th day while 227-252 microns on 30th day. Visual acuity improved from CF at onset to 0.4 on 5th day, 0.6 on 10th day and improved to 0.7 on 30th day.

Conclusion: This treatment modality is safe, affordable and easily available all over the world with early rehabilitation of acute CSC patients.

Keywords: treatment, bromfenac, central serous chorioretinopathy(csc), indus medical college hospital

(RPE) leakage.^{2,3} The disease has a favorable natural course with the spontaneous resolution of the neurosensory detachment in association with improvement of visual function. However, it is very difficult to predict the prognosis of CSC, and in some cases, progressive visual loss may be seen.^{4,5} Although the exact pathophysiology of CSC has not been clearly elucidated, the primary abnormality leading to RPE disruption and leakage is thought to be increased choroidal permeability.⁶ Studies using different imaging techniques have revealed the possible causes of abnormal permeability of the inner choroid. Ischemia and inflammation might lead to exudative changes within the choroid and the subsequent changes at the RPE.^{7,8}

Topical bromfenac, ketorolac, nepafenac and diclofenac all belong to the non-steroidal anti-inflammatory drugs (NSAIDs) class of medications. As an anti-inflammatory class, they function by inhibiting the enzyme cyclooxygenase, which blocks the synthesis of prostaglandins. A reduction in prostaglandin formation results decrease in inflammation. Inflammation makes the blood-retinal barrier more permeable. It appears that the principle pathway involved in pain and inflammation is the cyclooxygenase - 2 pathways where non-steroidal anti-inflammatory drugs NSAIDs seems to play a significant role. The current uses for topical NSAIDs have been somewhat limited to the prevention of intraoperative miosis (small pupil) during Phacoemulsification,^{9,10} relief of postoperative pain, inflammation and photophobia,¹¹ therapy for ocular atopy¹² and the reduction of post-cataract cystoid macular edema.¹³

Materials and methods

It is an interventional study conducted at Indus Medical College Hospital, Tando Mohammad Khan, from February to September 2017, includes 11 patients. Only patients with acute CSC included while those with chronic or recurrence were excluded. Careful history taken regarding sensitivity to bromfenac or any other non-steroidal anti-inflammatory drugs NSAIDs. All 11 patients were diagnosed as having acute CSC relying upon visual acuity by standard Snellen chart, dilated fundus exam using slit lamp with 90D lens and OCT (ocular coherence tomography) findings. All patients were treated by bromfenac topical drops twice daily. Patients followed on 5th day, 10th day and 30th day after presentation. Vision was recorded, dilated funduscopy and OCT performed on each visit.

All 11 patients were male (Table 1), divided into 3 age groups i.e. group A(21-30yrs) includes 6(54.54%) patients, group B (31- 40 yrs) includes 4(36.36%) patients and group C (41-50 yrs) includes 1(9.09%) patient (Table 2). 4(36.36%) were right eyes, 7(63.63%) were left (Table 3). Vision recorded using standard Snellen chart, 4(36.36%) patients having vision 0.4, 3 (27.27%) were 0.2, 2 (18.18%) were having 0.1 while remaining 2 (18.18%) were recorded as CF at 1 meter (Table 4). Macular thickness recorded using OCT, patients again divided into 3 groups on OCT findings, group 1, 5(45.45%) patients having macular thickness between 422-485 microns, group 2,

4(36.36%) patients between 535-565 microns while group 3, includes 2(18.18.%) patients having thickness between 612-644 microns (Table 5). All 11 patients received topical bromfenac, one drop twice daily to treat acute CSC for 10 days and monitor for 1 month.

Table 1 Male female ratio

Male	Female
11 (100%)	Nil

Table 2 Age groups

Group A(21-30yrs)	Group B(31-40yrs)	Group C(41-50yrs)
6(54.54%)	4(36.36%)	1(9.09%)

Table 3 Laterality

Right Eye	Left Eye
4(36.36%)	7(63.63%)

Table 4 Vision at onset

Patients	Vision
4(36.36%)	0.4
3 (27.27%)	0.2
2 (18.18%)	0.1
2 (18.18%)	CF at 1 meter

Table 5 Macular thickness at onset

Groups	Patients	Macular Thickness
1	5(45.45%)	422-485 microns
2	4(36.36%)	535-565 microns
3	2(18.18.%)	612-644 microns

Results

This interventional study includes 11 patients who were diagnosed as acute CSC and followed from the day of presentation to 30th day. All 11 patients were underwent intervention by using topical bromfenac eye drop, one drop twice daily for 30 days. Macular thickness and visual acuity recorded from the day of presentation up to 30th day. Table 6 shows all changes before and after treatment and Figure 1 a, b, c, d shows early resolution of sub-macular fluid in one of these patients treated with topical bromfenac eye drops (one drop twice daily). In group 1 the macular thickness (CFT) improve from

422-485 microns at onset to 317-382 microns on 5th day becomes 246-295 on 10 day while 210-226 on 30th day. Vision improved from 0.4 to 0.7 at 5th day, improved to 0.8 on 10th day and remained same on 30th day. In group 2 the CFT reduced from 535-565 microns to 401-440 microns on 5th day becomes 318-310 on 10th day and on 30th day it was 221-232 microns with improvement in visual acuity which was 0.2 at onset to 0.6 at 5th day, 0.7 at 10th day and improved to 0.8 on 30th day. In group 3 the CFT reduced from 612-644 microns to 560-595 microns on 5th day, 366-388 microns on 10th day while 227-252 microns on 30th day. Visual acuity improved from CF at onset to 0.4 on 5th day, 0.6 on 10th day and improved to 0.7 on 30th day.

Table 6 Macular thickness in microns and visual acuity before and after intervention with topical bromfenac eye drop

Days	Groups					
	1		2		3	
	CFT (Microns)	Vision	CFT (Microns)	Vision	CFT (Microns)	Vision
At onset	422-485	0.4	535-565	0.2	612-644	CF
5 th	246-295	0.7	318-310	0.6	560-595	0.4
10 th	210-226	0.8	221-232	0.7	366-388	0.6
30 th	210-226	0.8	221-232	0.8	227-252	0.7

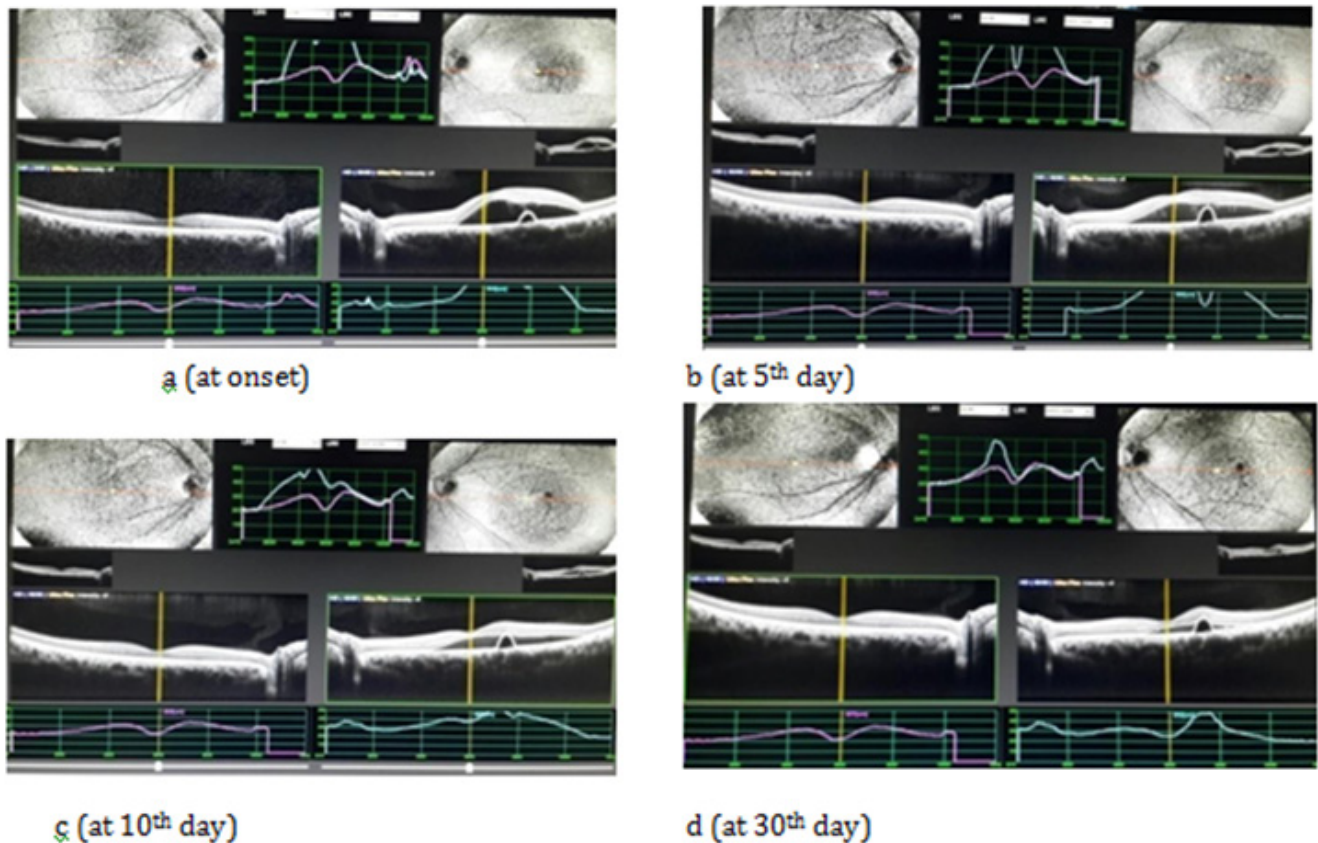


Figure 1 Showing reduction of CFT from 644 microns at onset to 595 microns at 5th day and 388 microns at 10th day while 252 microns at 30th day with only topical bromfenac eye drops.

Discussion

Central serous chorioretinopathy can lead to visual loss because of the accumulation of fluid in retinal layers for longer time that may lead to foveal attenuation, cystoid macular degeneration, and damage of the foveal photoreceptor layer.^{14–16} Some therapeutic intervention may be helpful to resorb this fluid quickly and avoid dyschromatopsia and metamorphopsia along with other visual problems. Variety of treatment modalities like focal argon photocoagulation, PDT, anti-VEGF, topical non-steroidal anti-inflammatory drug (NSAID) are being used. In this study we used only bromfenac, one of the non-steroidal anti-inflammatory drug NSAIDs as topical therapy. We did not use any intravitreal injection, laser or PDT. We found that macular thickness reduced very early and vision returned to normal in those patients who received topical bromfenac. In one study, Pradeep Venkatesh¹⁷ presented a contradictory opinion to what we found in this study. It is his experience but many studies are there along with this one to prove the effect of (NSAIDs) in the treatment of CSC. Lucia Villarroel Salvatierra et al.¹⁸ showed in their study that average macular thickness at center of the fovea before treatment was 431.55 microns, and post treatment macular average thickness was 198.77 microns though they treated CSR with Intravitreal bevacizumab along with laser. We got the same outcomes using bromfenac topical therapy. Zeynep Alkin and co workers¹⁹ used topical nepafenac 0.1%, and they have 82.3% results in resolution of macular sub retinal fluid at six months with the CFT decrease 349 microns to 257 at 1 month,

248 microns at 3 months and 221 at 6 months while in control group resolution was 42.8% with macular thickness reduced from 391 to 320 microns at 1 month 316 microns, at 3 months 301 microns and at six months 301 microns. We got better results using topical bromfenac only and within 10 days though we followed these patients for 1 month. Furthermore, no ocular or systemic side effects were observed in the treatment group during the follow-up period. Chan et al.²⁰ in their study, 63 patients treated with acute CSC using half-dose verteporfin PDT or placebo PDT in an attempt to demonstrate the safety of PDT. Subsequent to a follow-up time of 12 months, 94% of the eyes exhibited complete resolution of serous macular detachment in the half-dose PDT group versus only 57% of the eyes in the placebo group. Again, our results prove bromfenac topical therapy is more effective. While Artunay O et al.²¹ Ober et al.²² and Lim JW et al.²³ showed in their studies that treatment of acute CSC with intravitreal injections of anti-VEGF agents has variable outcomes. Our results with topical bromfenac were excellent and consistent.

Pikkel et al.²⁴ demonstrated limited recovery in CSC patients with acetazolamide. In addition, its use is limited because of its potential side effects. It has been proposed that corticosteroid antagonists could be used for treatment of acute CSC such as mifepristone and ketoconazole. However, trials with these drugs have proven unsuccessful^{25,26} Metoprolol and propranolol, another treatment strategy with adrenergic receptor inhibitors, should be used very cautiously because of its significant side effects and potential

morbidity.^{27,28} In our experience bromfenac shows better results without any side effects. This somehow proves that bromfenac topical therapy like other NSAIDs has its role for early rehabilitation of these patients suffering with acute CSC.

Conclusion

Many studies were conducted all over the world for the treatment of acute central serous chorioretinopathy using many modalities like argon photocoagulation for leaking spot, PDT, anti-VEGF injections, topical anti-inflammatory (NSAIDs) etc, all are having their worth but in our study, we used only topical bromfenac drops (one drop twice daily) and within 10 days, macular thickness as well as visual acuity came to almost at normal level. This treatment modality is safe, affordable and easily available.

Acknowledgments

I am thankful to Atiqa Khan (final year BDS), Aisha Khan (final year MBBS) students at Isra University Hospital Pakistan for their help in compiling data. Special thanks to Sobia Khan (second year MBBS) student at Indus Medical College Hospital and my assistant Mr. Moin Shaikh for their help to keep OCT record. I am also thankful to Dr. Aftab Ahmed Khan (assistant professor), at Indus Medical College Hospital, for his continuous support.

Conflicts of interest

Author declares that there are no conflicts of interest.

Funding

None.

References

- Jack J Kanski. Clinical Ophthalmology: A Systemic approach, 7th edn. 2011; p. 632.
- Wang M, Munch IC, Hasler PW, et al. Central serous chorioretinopathy. *Acta Ophthalmol.* 2008;86(2):126–145.
- Piccolino FC, Borgia L. Central serous chorioretinopathy and indocyanine green angiography. *Retina.* 1994;14(3):231–242.
- Loo RH, Scott IU, Flynn HW, et al. Factors associated with reduced visual acuity during long-term follow-up of patients with idiopathic central serous chorioretinopathy. *Retina.* 2002;22(1):19–24.
- Levine R, Brucker AJ, Robinson F. Long-term follow-up of idiopathic central serous chorioretinopathy by fluorescein angiography. *Ophthalmology.* 1989;96(6):854–859.
- Guyer DR, Yannuzzi LA, Slakter JS, et al. Digital indocyanine green videoangiography of central serous chorioretinopathy. *Arch Ophthalmol.* 1994;112(8):1057–1062.
- Tittl MK, Spaide RF, Wong D, et al. Systemic findings associated with central serous chorioretinopathy. *Am J Ophthalmol.* 1999;128(1):63–68.
- Prünte C, Flammer J. Choroidal capillary and venous congestion in central serous chorioretinopathy. *Am J Ophthalmol.* 1996;121(1):26–34.
- Ohara K, Ohbuto A, Miyamoto T, et al. Prevention of miosis during cataract surgery by topical bromfenac sodium. *Jpn J Clin Ophthalmol.* 2004;58:1325–1328.
- Data on file. ISTA Pharmaceuticals Xibrom US Phase 111 Trials.
- Seward MS, Cooke DL, Grillone LR, et al. *Topical Xibrom 0.09% Significantly Reduced Ocular Pain Following Cataract Surgery.* USA: Presented at ARVO, Fort Lauderdale, Florida; 2006.
- Miyake K, Masuda K, Shirato S, et al. Comparison of diclofenac and fluorometholone in preventing cystoid macular edema after small incision cataract surgery: a multicentered prospective trial. *Jpn J Ophthalmol.* 2000;44(1):58–67.
- Schainus R. Topical nonsteroidal anti-inflammatory therapy in Ophthalmology. *Ophthalmologica.* 2003;217(2):89–98.
- Piccolino FC, de la Longrais RR, Ravera G, et al. The foveal photoreceptor layer and visual acuity loss in central serous chorioretinopathy. *Am J Ophthalmol.* 2005;139(1):87–99.
- Iida T, Yannuzzi LA, Spaide RF, et al. Cystoid macular degeneration in chronic central serous chorioretinopathy. *Retina.* 2003;23(1):1–7.
- Shukla D, Kolluru C, Vignesh TP, et al. Transpupillary thermotherapy for subfoveal leaks in central serous chorioretinopathy. *Eye (Lond).* 2008;22(1):100–106.
- Pradeep Venkatesh. *Retinal Physician.* 2013;10:24–26.
- Salvatierra LV, Valenzuela VB, Suzuki MM. Study of Best Corrected Visual Acuity and Macular Thickness After Bevacizumab or Bevacizumab with Laser in Acute Central Serous Chorioretinopathy. *EC Ophthalmology.* 2016;4(4):569–578.
- Alkin Z, Osmanbasoglu OA, Ozkaya A, et al. Med Hypothesis Discov Innov Ophthalmol. Winter. 2013;2(4):96–101.
- Chan WM, Lai TY, Lai RY, et al. Half-dose verteporfin photodynamic therapy for acute central serous chorioretinopathy. *Ophthalmology.* 2008;115(10):1756–1765.
- Artunay O, Yuzbasioglu E, Rasier R, et al. Intravitreal bevacizumab in treatment of idiopathic persistent central serous chorioretinopathy: a prospective, controlled clinical study. *Curr Eye Res.* 2010;35(2):91–98.
- Ober MD, Yannuzzi LA, Do DV, et al. Photodynamic therapy for focal retinal pigment epithelial leaks secondary to central serous chorioretinopathy. *Ophthalmology.* 2005;112(12):2088–2094.
- Lim JW, Ryu SJ, Shin MC. The effect of intravitreal bevacizumab in patients with acute central serous chorioretinopathy. *Korean J Ophthalmol.* 2000;24(3):155–158.
- Pikkel J, Beiran I, Ophir A, et al. Acetazolamide for central serous retinopathy. *Ophthalmology.* 2002;109(9):1723–1725.
- Meyerle CB, Freund KB, Bhatnagar P, et al. Ketoconazole in the treatment of chronic idiopathic central serous chorioretinopathy. *Retina.* 2007;27(7):943–946.
- Nielsen JS, Jampol LM. Oral mifepristone for chronic central serous chorioretinopathy. *Retina.* 2011;31(9):1928–1936.
- Avcı R, Deutman AF. Treatment of central serous choroidopathy with the beta receptor blocker metoprolol (preliminary results). *Klin Monbl Augenheilkd.* 1993;202(3):199–205.
- Ratanasukon M, Bhurayanontachai P, Jirattanasopa P. High-dose antioxidants for central serous chorioretinopathy; the randomized placebo-controlled study. *BMC Ophthalmol.* 2012;20:20.