

Options of irradiating intraocular melanoma at linear accelerator: a mini review

Abstract

Primary tumors of the eye are rare but important malignant lesions. They represent less than 0.2% of all cancers. Primary malignant uveal melanoma is the most common primary tumor of the eye-it constitutes more than 80% of primary eye tumors. This tumor is seen in older patients, with nearly equal frequency in males and females. More than 80% of uveal melanomas arise from the choroid. New irradiation techniques become in recent years the treatment of choice in all patients with melanomas (except very large ones -stage T3,T4) where an enucleation is indicated. The treatment by linear accelerator stereotactic radiosurgery (LSRS) is indicated in small tumors (stage T1,T2). Survival is comparable to all conservative treatments. Complications, such as a cataract, radiation papillitis, radiation maculopathy, secondary glaucoma, decrease due to early indication of posterior uveal melanoma treatment. Linear accelerator can range required the dose of irradiation in optimally localized target-volume at minimum loading of ambient. The incidence of extracerebral malignant head and neck tumors in general population is relatively high. Long term results show us the effectiveness of this method to treat radiosurgically also the extracerebral pathological lesions under skull base at neck up to C3-level and in maxillofacial area. LSRS may be used as a main and primary treatment of uveal melanomas to prevent the enucleation. The residual tumor control is also high recently.

Keywords: intraocular tumor, stereotactic irradiation, uveal melanoma

Volume 6 Issue 4 - 2017

Pavlina Justusova,¹ Jan Juhas,¹ Branislav Sepesi,² Maria Fribertova,³ Robert Furda⁴

¹Department of Ophthalmology, Comenius University, Slovakia

²Department of Stereotactic Radiosurgery, St. Elisabeth Cancer Inst. and St. Elisabeth University College of Health and Social Work, Slovakia

³Institute of Medical Physics of St. Elisabeth Cancer Inst, Slovakia

⁴Department of Information Systems, Comenius University, Slovakia

Correspondence: Pavlina Justusova, Department of Ophthalmology, Medical School, Comenius University, Bratislava, (Klinika oftalmologie LFUK a UNB), Hospital Ruzinov Ruzinovska 682606, Bratislava, Slovakia, Tel +421248234607, Email pjustusova@gmail.com

Received: March 08, 2017 | **Published:** March 31, 2017

Abbreviations: LSRS, linear accelerator stereotactic radiosurgery; CT, computed tomography; MRI, magnetic resonance imaging; PET/CT, positron emission tomography; ROI, region of interest; PD, papillary diameter; LINAC, linear accelerator; Gy, gray-unit of absorbed radiation

Introduction

Ophthalmic oncologists know that in adults the most common and the most aggressive type of cancer is the intraocular melanoma. The similarities in incidence of the related uveal melanoma can be found in the United States with approximately 4.3 new cases per million inhabitants. In European countries the number is similar. In Slovakia the value varies from 0.2 to 0.6 per one hundred thousand.^{1,2} Intraocular melanoma prognostic indicators are age of the patient and tumor volume (or tumor size). Nowadays ophthalmologists have the possibility to diagnose primary uveal melanoma by using the newest diagnostic tools, such as ultrasound, optical coherence tomography, computed tomography (CT), magnetic resonance imaging (MRI), and positron emission tomography (PET/CT). These diagnostic tools allow among others to practice also radiotherapy treatment, such as brachytherapy and other modalities (stereotactic radiotherapy, proton beam irradiation, and Leksell Gama Knife), which becomes the preferred treatment method for the overwhelming majority of uveal melanoma patients. During the last two decades stereotactic radiosurgery of extracerebral lesions, such as uveal melanoma, is used by small and medium stage posterior uveal melanoma treatment. It provides good local control which brings the results to survival rates as good as other treatments.³⁻⁵

For over twenty years stereotactic photon beam irradiation for the treatment of uveal melanoma has been under clinical investigation. Single-fraction stereotactic radiosurgery can be done with a gamma knife or a cyberknife. The therapeutic single dose has been reduced to as low as 35 Gy over the past few years without reduction in tumor control. One-fraction linear accelerator - LINAC radiotherapy, as a kind of radiosurgery, is not so widespread approach in choroidal melanoma treatment. There the image fusion of a contrast, the enhanced MRI with CT, is used in three-dimensional treatment planning and its coordinates' calculations. This treatment is a LSRS way with the single fraction 35.0 Gy which is administered with a high spatial accuracy using a collimating system. The team of specialists consists of one ophthalmologist, one neurosurgeon and one medical physicist. All of them are responsible for LSRS planning. The mentioned image fusion of a contrast is appropriate for accurate specifying of the affected anatomical structures: the targeted volume differentiation of tumor mass, of healthy tissue, and of the most critical structures (optic chiasm, brain stem, skin of the eyelids, bilateral optic nerves and lenses). Exact planning is very important in determining the stereotactic coordinates of radiation beams that apply into targeted tumor mass. Irradiation of critical structures by inappropriate doses can lead to loss of vision or other complications, and it can reduce quality of life after the therapy.⁶

Choroidal melanoma has a well-documented capacity to metastasize hematogenously. The liver is the most common site of metastatic disease.⁷ Patients with uveal melanoma are screened for metastasis 6-monthly using liver function tests and imaging studies. Enucleation, such as standard method in treatment of posterior

uveal melanoma, are questioned for longer than 30 years, so-called conservative treatment methods are used with some success, destroying the tumor and preserving vision. After experiments it was shown that is possible to destroy intraocular tumors by irradiation. Radiation therapy (radiotherapy with external charged particle beams or applicators) is increasingly engaged in recent years. Nowadays, the brachytherapy is one successful method in choroidal melanoma treatment. Conservative treatment with radiation therapy can arrest and reverse tumor growth in a high percentage of cases. Unfortunately, the most serious late complication after treatment, such as rubeosis iridis with neovascular glaucoma and cataract, is developed in about from 15% to 30% in patients after external beam irradiation.^{8,9}

Stereotactic irradiation

In consideration, what kind of treatment is needed to take into account, the stage, the size, or volume of the tumor is important. The others are maximum elevation and secondary retinal detachment, also general status, age, gender, the functional tests, visual acuity, and visual field. The information about the therapeutic procedure and possible postoperative complications is actively interpreted to the patient before his/her final decision to start the treatment. The tumor volume is calculated using the formula: $\text{volume} = \pi/6 \times \text{length} \times \text{width} \times \text{height}$. Tumors are divided by volume into three groups as follows: the small ones are less than 0.5 cm³, the medium ones are from 0.5 to 1.0 cm³ and the large ones are over 1.0 cm³.

To achieve the immobilization of the treated eye the kind of surgical fixation of the eye globe muscles to the stereotactic Leibinger frame is needed. It is provided in three steps by using the local anesthesia: the special sutures are placed under to four direct extraocular muscles through conjunctiva and through the lids (usually done one day before treatment), the stereotactic frame is fixed onto the head at specific points, and the prepared sutures are fixed at the stereotactic frame. Just after the surgical fixation is done the patient passes both the CT and the MRI scan procedures.

Then the image fusion of CT and MRI contrast is used to calculate the stereotactic treatment planning scheme. The scheme is accordingly optimized against critical structures of the affected eye, such as lens, optic nerve and chiasm (Figure 1). Volume of the tumor influences the calculation of the planned 35.0 Gy therapeutic dose. LSRS is performed on linear accelerator with 6 MeV X. During irradiation at linear accelerator the doses to the critical structures are: less than 8.0 Gy for the optic nerve and the optic disc, and less than 10.0 Gy to the anterior segment of the eye. Just after the LSRS is done the sutures and frame are removed under local anesthesia. Patients after LSRS are followed in three months interval by an ophthalmologist (biomicroscopy, ophthalmoscopy, applanation tonometry, ultrasound, optical coherence tomography) and in six month interval are screened by MRI of the orbit plus metastasis screening (liver ultrasound, liver function test; chest X-ray).

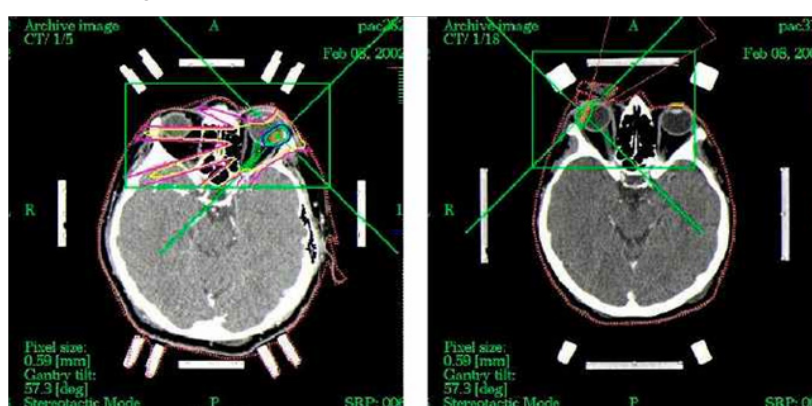


Figure 1 Two examples of computer images with calculated and optimized LSRS dose planning scheme for malignant uveal melanoma treatment.

Discussion

Nowadays the management of uveal melanoma patients changed towards to globe sparing techniques. Enucleation is not so frequent; there are other options such as block-excision, endoresection or radiotherapy which includes brachytherapy, Leksell Gama Knife, stereotactic irradiation, proton beam irradiation, and others.¹⁰⁻¹² The efficacy of LSRS for uveal melanoma is described in different studies where the local tumor control rates are over 90%.¹³⁻¹⁵ High rates of local control are achieved with five year control exceeding 95% in patients treated with proton-beam irradiation.¹⁶ Other studies compare LSRS with brachytherapy which have similar metastasis rate, local tumor control rate, complications rate and mortality rate.¹⁷ LSRS is feasible and well tolerated too. It can be offered to medium sized and unfavorably located uveal melanoma as an eye globe preserving treatment.¹⁸

Uveal melanoma, with rare exception, metastasizes hematogenously. In the study of Grossniklaus show that, importantly, subclinical stage 1 metastases are present in the livers of patients

with metastatic uveal melanoma. As tumors progress and enlarge, they become vascularized, and mitotic activity is demonstrable. The hypothesis generated from the study of Zimmerman et al.¹⁹ qualified the effect of increased clinically detectable metastases and questioned, whether the enucleation of the eye containing a malignant melanoma prevent or accelerate the dissemination of tumor cells. The comparison of mortality rates for medium-sized melanomas treated by enucleation, brachytherapy or LSRS is in few prospective, randomized trials only available.^{20,21} Gamma knife radiosurgery and LSRS in the latest studies are suggested to be an appropriate alternative to treat uveal melanoma in cases, where the brachytherapy is not available or suitable. To preserve the eye globe is the main goal in conservative treatment. Secondary neovascular glaucoma as complication after LSRS is the most frequent reason for enucleation; it varies from 10 % to 20 %.²² Single dose one-day session LSRS with 35.0 Gy is adequate to treat small and medium stage melanoma.²¹

Radiogenic tissue damage must be expected when dealing with the radiosensitive structures of the eye, even after local β -irradiation.

Exudative reactions are occurring a few days after irradiation, such as chemosis, choroidal detachment and transient retinal detachment should not be regarded as serious complications because of their good prognosis. Radiogenic side effects must be taken into consideration in all radiation techniques, but with β -rays they can be limited. Severe radiogenic chorioretinopathy were seen in some cases. Most of patients with a tumor located 1-2 papillary diameters (PD) from the posterior pole show destruction of the macula because of the scarring process. In the absence of a biopsy it is possible that some of the small tumors responding favorably to brachytherapy may have been benign lesions, thereby improving the results. To overcome this uncertainty some ophthalmologists recommend that the morphology of intraocular tumors can be established by transvitreal retinochoroidal biopsy. Despite these advantages, some complications occur, mainly due to the fact that about 50% of the treated tumors are located close to the fovea or the optic disc and about 50% of them are more than 5 mm in height. Significant predictors for the appearance of lens opacities were: age, tumor height, localization of anterior tumor margin and irradiation of the periphery of the lens.

Glaucoma is the most important reason for enucleation after LSRS. Large tumors and older patients were particularly subject to glaucoma when the optic disc had to be irradiated because of tumor size or its location. Rubeosis iridis develops in all cases with development of secondary glaucoma. The contributors to it were tumor elevation, irradiation of the optic disc, the largest tumor diameter and the extension of a retinal detachment. Patients with large tumors near the optic disc and a large retinal detachment are more subject to rubeosis. Important prognostic factors for death from metastatic melanoma include the size of the tumor (the larger the tumor, the worse the prognosis), the location of the tumor, the age of the patient at the time of diagnosis (the older the patient, the worse the short-term survival prognosis) and extrascleral tumor extension.

Preservation of the eye and useful vision in many patients are the obvious advantages of conservative treatment with radiation compared with enucleation. However questions have been raised regarding the efficacy of this treatment in limiting metastatic spread of the tumor. Observational studies comparing irradiation with enucleation have indicated no significant differences in survival rates. Proton irradiation is highly successful in achieving local control of intraocular melanoma. Overall rates of metastatic disease are comparable to those observed after enucleation; thus, enucleation should be limited to patients with large tumors in whom the eye is unlikely to be salvaged by irradiation. Doubtless continued refinement of current methods, and development of new techniques, will further improve the outlook of patients with uveal melanomas.²³

Conclusion

One-day session LSRS with 35.0 Gy is a way to treat small and medium stage uveal melanoma. Survival rates in 5 year interval and necessity of secondary enucleation due to complications after one day session linear accelerator irradiation is comparable to other techniques.²⁴

Funding

None.

Acknowledgments

None.

Conflicts of interest

Authors declare that there is no conflict of interest.

References

1. Singh AD, Turell ME, Topham AK. Uveal melanoma: trends in incidence, treatment, and survival. *Ophthalmology*. 2011;118(9):1881–1885.
2. Furdová A, Oláh Z, Svetlošáková Z, et al. The current state of the evidence of malignant tumors of the eye and its adnexa (dg. C69) in the Slovak Republic and in the Czech Republic. *Cesk Slov Ophthalmol*. 2012;68(5):195–201.
3. Furdova A, Sramka M. Uveal malignant melanoma and stereotactic radiosurgery. Germany: LAP LAMBERT Academic Publishing, Saarbrücken; 2014. p. 188.
4. Cohen VM, Carter MJ, Kemeny A, et al. Metastasis-free survival following treatment for uveal melanoma with either stereotactic radiosurgery or enucleation. *Acta Ophthalmol Scand*. 2003;81(4):383–388.
5. Damato B, Kacperek A, Chopra M, et al. Proton beam radiotherapy of choroidal melanoma: the Liverpool-Clatterbridge experience. *Int J Radiat Oncol Biol Phys*. 2005;62(5):1405–1411.
6. Furdova A, Strmen P, Waczulikova I, et al. One-day session LINAC-based stereotactic radiosurgery of posterior uveal melanoma. *Eur J Ophthalmol*. 2012;22(2):226–235.
7. Collaborative Ocular Melanoma Study Group. Assessment of metastatic disease status at death in 435 patients with large choroidal melanoma in the Collaborative Ocular Melanoma Study (COMS): COMS report no. 15. *Arch Ophthalmol*. 2001;119(5):670–676.
8. Diener-West M, Reynolds SM, Agugliaro DJ, et al. Screening for metastasis from choroidal melanoma: the Collaborative Ocular Melanoma Study Group Report 23. *J Clin Oncol*. (2004) 22(12): 2438-2444.
9. Diener-West M, Reynolds SM, Agugliaro DJ, et al. Development of metastatic disease after enrollment in the COMS trials for treatment of choroidal melanoma: Collaborative Ocular Melanoma Study Group Report No. 26. *Arch Ophthalmol*. 2005; 123(12):1639–1643.
10. Henderson MA, Shirazi H, Lo SS, et al. Stereotactic radiosurgery and fractionated stereotactic radiotherapy in the treatment of uveal melanoma. *Technol Cancer Res Treat*. 2006;5(4):411–419.
11. Dieckmann K, Dietmar G, Bogner J, et al. Optimizing LINAC-based stereotactic radiotherapy of uveal melanomas: 7 years' clinical experience. *Int J Radiation Oncology Biol Phys*. 2006;66(4):S47–S52.
12. Mosci C, Mosci S, Barla A, et al. Proton beam radiotherapy of uveal melanoma: Italian patients treated in Nice, France. *Eur J Ophthalmol*. 2009;19(4):654–660.
13. Mueller AJ, Talies S, Schaller UC, et al. Stereotactic radiosurgery of large uveal melanomas with the gamma-knife. *Ophthalmology*. 2000;107(7):1381–1387.
14. Krema H, Somani S, Sahgal A, et al. Stereotactic radiotherapy for treatment of juxtapapillary choroidal melanoma: 3-year follow-up. *Br J Ophthalmol*. 2009;93(9):1172–1176.
15. Dieckmann K, Georg D, Zehetmayer M, et al. LINAC based stereotactic radiotherapy of uveal melanoma: 4 years clinical experience. *Radiother Oncol*. 2003;67(2):199–206.
16. Meyer A, Lévy C, Blondel J, et al. Optic neuropathy after proton-beam therapy for malignant choroidal melanoma. *J Fr Ophthalmol*. 2000;23(6):543–553.
17. Ghazi NG, Ketcherside CS, Sheehan J, et al. Gamma knife radiosurgery for uveal melanoma ineligible for brachytherapy by the Collaborative Ocular Melanoma Study criteria. *Open Access Surg*. 2008;1:21–24.

18. Furdova A, Sramka M, Chorvath M, et al. Stereotactic radiosurgery in intraocular malignant melanoma--retrospective study. *Neuro Endocrinol Lett.* 2014;35(1):28–36.
19. Grossniklaus HE. Progression of ocular melanoma metastasis to the liver: the 2012 Zimmerman lecture. *JAMA Ophthalmol.* 2013;131(4):462–469.
20. Singh AD, Shields CL, Shields JA. Prognostic factors in uveal melanoma. *Melanoma Res.* 2001;11(3):255–263.
21. Furdova A, Slezak P, Chorvath M, et al. No differences in outcome between radical surgical treatment (enucleation) and stereotactic radiosurgery in patients with posterior uveal melanoma. *Neoplasma.* 2010;57(4):377–381.
22. Furdová A, Sramka M, Thurzo A, et al. Early experiences of planning stereotactic radiosurgery using 3D printed models of eyes with uveal melanomas. *Clin Ophthalmol.* 2017;11:267–271.
23. Koutsandrea C, Moschos MM, Dimissianos M, et al. Metastasis rates and sites after treatment for choroidal melanoma by proton beam irradiation or by enucleation. *Clin Ophthalmol.* 2008;2(4):989–995.
24. Furdová A, Sramka M, Chorvath M, et al. Linear Accelerator Stereotactic Radiosurgery in Intraocular Malignant Melanoma. *Austin J Radiat Oncol & Cancer.* 2015;1(2):1008.