

# YAG membranotomy for persistent postoperative fibrinous pupillary membrane in an aphakic patient with silicone oil

## Abstract

We report a case of using Nd:YAG laser to perform a membranotomy of a persistent dense fibrinous pupillary membrane at the silicone oil (SO) interface in an aphakic patient following pars plana vitrectomy (PPV), pars plan lensectomy(PPL) with SO placement. Nd:YAG laser was successfully used to create a central opening in the fibrinous membrane at the SO interface which allowed for the proper examination of the posterior segment and improvement in the patient's visual acuity.

**Keywords:** fibrinous membrane, pupillary membrane, silicone oil, pars plana vitrectomy, aphakia, YAG laser

Volume 4 Issue 1 - 2016

Lamba N,<sup>1</sup> Asano MK,<sup>1</sup> Anderson E,<sup>1</sup> Skondra D<sup>1,2</sup>

<sup>1</sup>Vitreoretinal Service, John Stroger Hospital of Cook County, USA

<sup>2</sup>Retina Service, Northwestern Feinberg School of Medicine, USA

**Correspondence:** Dimitra Skondra, J Stroger Cook County Hospital, 161 W Kinzie Street Apt 2501 Chicago IL 60654, USA, Tel 8572049493, Email dimitraskondra@gmail.com

**Received:** November 11, 2015 | **Published:** January 13, 2016

**Abbreviations:** SO, silicone oil; PPV, pars plana vitrectomy; PPL, pars plan lensectomy; TPA, tissue plasminogen activator

## Introduction

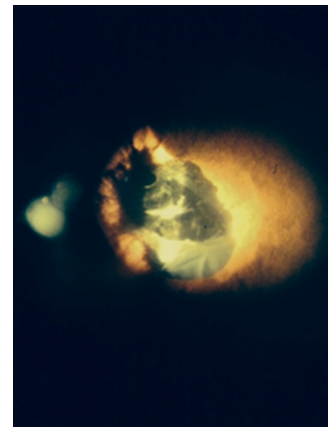
Fibrinous pupillary membranes can develop after intraocular surgery and consist of precipitates of inflammatory cells, pigment and fibrin. Formation of intraocular fibrin following vitrectomy surgery is a potentially serious complication that may lead to surgical failure. They usually can be resolved with topical corticosteroid therapy, but, in some cases, can persist despite aggressive topical treatment.<sup>1</sup> Nd:YAG lasers have been known to be used for the treatment of opacification of the remaining posterior capsule and for the treatment of pupillary membranes after cataract surgery but have never been described for the management of fibrinous pupillary membranes at the SO interface in aphakic patients after PPV.<sup>2,3</sup>

## Case report

A 47-year-old poorly controlled diabetic male presented with dense vitreous hemorrhage and evidence of bullous macula off inferior retinal detachment on the ultrasound in the setting of proliferative diabetic retinopathy and preoperative vision of hand motion. He underwent scleral buckle placement, pars plana vitrectomy (PPV), pars plana lensectomy (PPL) with complete removal of the posterior and anterior lens capsule, inferior peripheral iridotomy, membrane peeling, inferior retinectomy, endolaser and silicon oil (SO) placement in the right eye for the treatment of a macula off combined rhegmatogenous and tractional retinal detachment with severe diabetic fibrovascular proliferation and severe proliferative vitreoretinopathy with preretinal and subretinal membranes.

Examination at post-operative week one revealed a dense fibrinous membrane at the pupillary margin on the anterior surface of the SO bubble, attached to the pupillary ruff for 360 degrees (Figure 1). Visual acuity was hand motion and intraocular pressure was 12. The

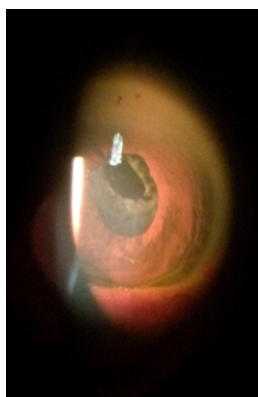
patient was maintained on topical treatment with prednisolone acetate 1% every hour and topical atropine sulfate 1% once a day. Despite compliant use of the medications, the dense pupillary membrane persisted at post-operative month one and visual acuity remained hand motion and there was very limited view to the fundus to assess retina.



**Figure 1** Anterior segment photo showing dense pupillary membrane at post-operative week one.

After extensive discussion with the patient and proper written consent, Nd:YAG laser (Coherent Lumenis Aura, Santa Clara, CA) was used to perform a membranotomy. The laser was delivered through a Yag capsulotomy contact lens with an energy level set at 2.2 MJ with one pulse per burst. An opening approximately 3x3mm was created centrally in the pupillary membrane, making sure the visual axis was clear. Right after laser, a small bubble of SO was noted in the anterior chamber. Patient was instructed to maintain face down position for 24 hours and exam next day showed that SO bubble and moved to posterior chamber and normal intraocular pressure and mild inflammation.

The patient was continued on prednisolone 1% for his right eye. One week after the laser treatment, exam showed a patent opening in the pupillary membrane (Figure 2), minimal inflammation in the anterior chamber and vision had improved to 20/200, IOP was 9 and dilated fundus exam showed attached retina under SO. At 18 months follow up after the Nd:YAG laser procedure, visual acuity was 20/250 and IOP was 8. Anterior segment exam showed a patent central opening through the pupillary membrane, SO at the pupillary place and a clear view of an attached retina under SO with mild epiretinal membrane in the macula.



**Figure 2** Anterior segment photo showing patent central membranotomy 1 week after Nd:YAG laser treatment.

## Discussion

Fibrinous pupillary membranes may form in the early postoperative period after intraocular surgery. Formation of intraocular fibrin following vitrectomy surgery is a potentially serious complication that may lead to surgical failure and can be very challenging to manage. It is believed that postoperative inflammation disrupts the blood-aqueous and blood-retina barrier, allowing plasma proteins, including fibrin, to enter the anterior chamber.<sup>4</sup> Multiple studies have proposed that inflammation after intraocular surgery may affect the blood-aqueous and blood-retina barrier more severely in patients with uncontrolled diabetes and that patient with complications of proliferative diabetic retinopathy seem to have a high incidence of clinically important fibrin formation.<sup>5,6</sup>

Our patient had a significant post-operative fibrinous membrane at the SO interface that limited his visual acuity and did not allow for proper evaluation of the fundus. There was no evidence of resolution with topical steroid therapy over a period of 4 weeks and the decision was made to use Nd:YAG laser to create a central opening in the membrane as an alternative non surgical modality. Juarez et al.<sup>3</sup> first reported on the efficacy and safety of performing membranectomies through a pars plicata or pars plana approach. However, in our patient we opted to perform Nd:YAG laser because it is a much less invasive procedure and carries fewer complications compared to pars plana membranectomy. Nd:YAG laser is routinely used to perform a posterior capsulotomy in patients who have undergone cataract surgery with intraocular lens implant who present with posterior capsular opacification.

However, unlike posterior capsules, which are usually thin and under tension, post-operative secondary membranes can be dense with little elastic properties. Nd:YAG laser treatment has been shown to be effective in resolving secondary pupillary membranes after anterior

segment surgery in several case series as well as in a randomized trial conducted by Angra et al.<sup>6-8</sup> The density and type of membrane should be thoroughly evaluated to determine if intervention with laser treatment is appropriate. In our case, all the anterior and posterior capsule was removed during the pars plana lensectomy so we were confident that the membrane consisted only with fibrinous material and not capsular or lens material. To our knowledge, Nd:YAG laser has not been reported for the treatment of fibrin membranes at the SO interface in aphakic eyes after PPV and PPL with complete capsule removal.

Extensive treatments and the use of high pulse energy can release large amounts of membrane material and cause significant inflammation and elevated intraocular pressure. In our patient, only mild inflammation was noted after the laser membranotomy which was treated with topical steroids and the central opening remained patent for 18 months. We were concerned that Nd:YAG laser could disrupt the SO interface and cause migration of SO bubbles in the anterior chamber that could lead to conchal decompression and elevated intraocular pressure. Only a small bubble was noted in the anterior chamber just after the laser which was resolved after face down positioning for 1 day and SO has remained at the pupillary plane up to the most recent follow up.

Another possible treatment option for post-operative fibrinous pupillary membranes is the injection of recombinant tissue plasminogen activator (tPA) into the anterior chamber. Recombinant tPA is a potent fibrinolytic protein that has been safely used as a treatment to lyse postoperative fibrinous pupillary membranes. However, tPA has been found to only be effective in the early stages of membrane formation.<sup>9,10</sup> This approach was not considered in our patient because the organized fibrinous nature of the pupillary membrane. Furthermore, our patient was aphakic with SO and the effect and pharmacokinetics of tPA injected in SO filled eyes are unknown. For our patient, Nd:YAG laser membranotomy was successful in creating a central opening of the fibrinous membrane improving the patient's visual acuity and enabling detailed serial fundus examinations. No issues with significant inflammation, elevated intraocular pressure or SO migration were encountered.

To our knowledge, this is the first time Nd:YAG laser has been used successfully for membranotomy in an aphakic eye with severe fibrinous membrane formation at the SO interface that is unresponsive to topical treatment. YAG laser membranotomy could be considered as a non surgical alternative therapeutic modality to enable fundus visualization and improve visual acuity in these cases however further experience will better define the risk-benefit ratio.

## Acknowledgments

None.

## Conflicts of interest

The author declares there is no conflict of interest.

## References

1. Gandham SB, Brown RH, Katz LJ, et al. Neodymium: YAG membranectomy for pupillary membranes on posterior chamber intraocular lenses. *Ophthalmology*. 1995;102(12):1846-1852.
2. Norris JW, Chirls IA, Santry JG, et al. Severe fibrinous reaction after cataract and intraocular lens implantation surgery requiring neodymium:YAG

- laser therapy. *J Cataract Refract Surg.* 1990;16(5):637–639.
3. Juarez CP, Peyman GA, Raichand M, et al. Secondary pupillary membranes treated by the pars plana/pars plicata approach: long-term results of 108 cases. *Br J Ophthalmol.* 1981;65(11):762–766.
  4. Ben Simon GJ, Kenet G, Spierer A. Fibrinoid reaction after lens extraction in rabbit eyes. *J Cataract Refract Surg.* 2012;38(5):890–893.
  5. Liu Y, Luo L, He M, et al. Disorders of the blood-aqueous barrier after phacoemulsification in diabetic patients. *Eye (Lond).* 2004;18(9):900–904.
  6. Krupsky S, Zalish M, Oliver M, et al. Anterior segment complications in diabetic patients following extracapsular cataract extraction and posterior chamber intraocular lens implantation. *Ophthalmic Surg.* 1991;22(9):526–530.
  7. Kozobolis VP, Pallikaris IG, Tsambarlakis IG, et al. Nd YAG laser removal of pupillary membranes developed after ECCE with PC-IOL implantation. *Acta Ophthalmol Scand.* 1997;75(6):711–715.
  8. Viridi M, Beirouty Z, Saba SN. Neodymium:YAG laser discussion of postoperative pupillary membrane: peripheral photodisruption. *J Cataract Refract Surg.* 1997;23(2):166–168.
  9. Angra SK, Rai CB, Kalra VK. Management of secondary pupillary membrane in aphakia (YAG discission vs parsplana membranectomy). *Indian J Ophthalmol.* 1991;39(4):154–158.
  10. Heiligenhaus A, Steinmetz B, Lapuente R, et al. Recombinant tissue plasminogen activator in cases with fibrin formation after cataract surgery: a prospective randomised multicentre study. *Br J Ophthalmol.* 1998;82(7):810–815.