

Judet's Quadricepsplasty for Extension Contracture of the Knee (Stiff Knee)

Abstract

Between January 2003 to 2013 Judet's Quadricepsplasty was performed on 32 stiff knees. The initial preoperative range of movement was 15° (range 10°-25°). Postoperative plaster immobilization was only for 1 day. The mean follow up period was 6 years (range 2-10 years). During our follow up the mean active flexion was 70° (range 60°-120°). Final outcome in knee movement was 90° (40°-175°). In our series six patients developed wound dehiscence which resolved after meticulous wound care and antibiotics. In our all the cases we believe that Judet's Quadricepsplasty gives excellent result with proper postoperative care and CPM therapy.

Keywords: Judet, Quadricepsplasty, Knee extension contracture

Volume 2 Issue 6 - 2015

Bari MM,¹ Shahidul Islam,¹ NH Shetu,¹
 Wahidur Rahman,² Mahfuzer Rahman,¹
 Mashiur H Munshi,² Golam Mostofa¹

¹Chief Consultant, Bari-Ilizarov Orthopaedic Centre, Visiting and Honored Prof., Russian Ilizarov Scientific Centre, Russia

²National Institute of Traumatology and Orthopaedic Rehabilitation, Bangladesh

Correspondence: Mofakhkharul Bari, Chief Consultant, Bari-Ilizarov Orthopaedic Centre, Visiting and Honored Professor, Russian Ilizarov Scientific Centre, Kurgan, Tel +88 01819 211595, Email bari.ilizarov31@gmail.com

Received: April 14, 2015 | **Published:** June 15, 2015

Introduction

Extension contracture or stiff knee is a complication of fracture femur, particularly in the supracondylar area. Adequate knee flexion may not be possible, if we don't do the proper exercises postoperatively. After a fracture in the femoral supracondylar region, some difficulty always remains in regaining a full range of motion. In most of our cases stiffness is due to the periarticular and intramuscular adhesions which prevent free gliding of the muscle fibres one upon another. If stiff knee is severe and not possible by conservative treatment by exercises the knee movement can be increased by Judet's quadricepsplasty. The pathological abnormalities that limit knee flexion include.^{1,2}

1. Intra articular adhesions to complete arthrofibrosis.
2. Capsular contracture.
3. Quadriceps muscle contracture and adhesions to bone.
4. Fascial contractures and
5. MCL contracture

The treatment of knee extension contracture must therefore vary from simple arthroscopy to lyse adhesions to more extensive quadricepsplasty. Quadricepsplasty can be divided into distal and proximal types. Distal quadricepsplasty, such as the Thompson or V-Y types, should never be performed in adults because it leads to permanent knee extension lag. This may occur in children as well, but because the children are growing and retensioning their quadriceps muscle, it may recover. The best way of obtaining knee flexion is the Judet's Quadricepsplasty.^{1,2} This is a proximally based quadriceps muscle slide that addresses all the elements of the knee contracture. It was popularized by Letournel. The Judet's quadricepsplasty is a stepwise release of the knee and quadriceps muscle. Each successive step determines whether one continues with the next step of the release depending on the amount of knee motion recovered.

In our series Judet's quadricepsplasty for stiff knee was done on 32 cases from January 2003 to January 2013 with proper postoperative

management with CPM machine in an attempt to improve the knee range of motion.

Materials and methods

This study was conducted in NITOR (National Institute of Traumatology and Orthopaedic Rehabilitation, Dhaka) and BARI-ILIZAROV Orthopaedic Centre between January 2003 to January 2013. The mean age of the patient was 26 years (20-35 years) and the total number of patients were 32. All patients were male. All the patients developed stiff knee after periarticular knee fractures or Ilizarov application.

We retrospectively reviewed the results of 32 cases of knee extension contracture managed with Judet's quadricepsplasty during the last 10 years having a mean follow up of 24 months. Degrees of flexion of the operated knees preoperatively and at last follow up were recorded along with quadriceps strength, presence of extension lag and complications.

Outcomes were classified according to Judet's criteria:

1. Excellent, if flexion was greater than 100°.
2. Good, from 80° to 100°.
3. Fair, from 50° to 80°.
4. Poor, if less than 50°.

Surgical technique

The incision is marked for the full length of the thigh from the rough line of the greater trochanter to the lateral aspect of the patellar tendon. During surgical intervention we must give emphasis with these following 5 steps:^{1,3}

Step-1 (Intra articular release): Under tourniquet, only the distal part of the incision is made to release the knee adhesions from the lateral side.

Step-2: MCL and Medial capsular release Medial capsule is cut from a short medial incision; artholysis is performed. MCL is elevated off the tibial distally.

Step-3 (Rectus femoris release): With a small bikini line inguinal incision of approximately 3 to 4 cm is made, the rectus is identified and is transected.

Step-4(Quadriceps muscle slide): This incision is extended proximally to the greater trochanter. The tourniquet must be removed. The quadriceps is elevated off the femur along the intramuscular septum. The perforating vessels are ligated or cauterized. Vastus lateralis fascia is cut laterally.

Step-5: Fractional lengthening of Fasia lata and anterior Fasia of Thigh.

Finally we must release the fascia lata. It should not be separated from the skin to avoid skin necrosis. Transverse incisions at multiple levels can be made across the fascia lata and anterior thigh fascia. At this point, the knee should be able to be flexed fully with the skin, subluxing medially. No attempt should be made to close the knee capsule.

Surgical steps: (Figures 1-6)

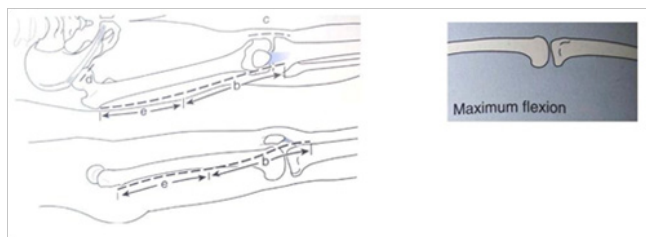


Figure 1 Incisions for Judet quadricepsplasty.

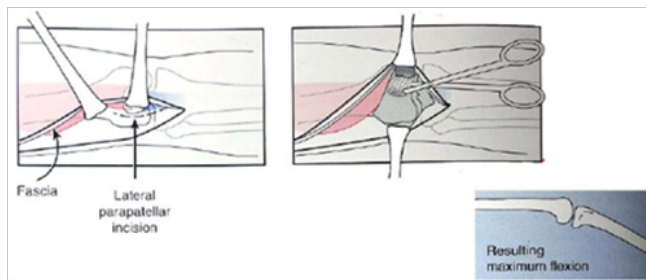


Figure 2 Incisions for Judet quadricepsplasty.

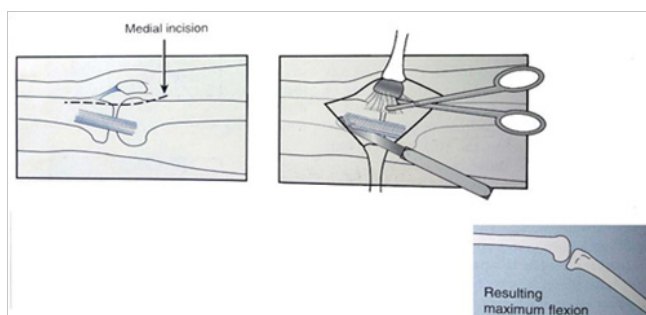


Figure 3 Incisions for Judet quadricepsplasty.

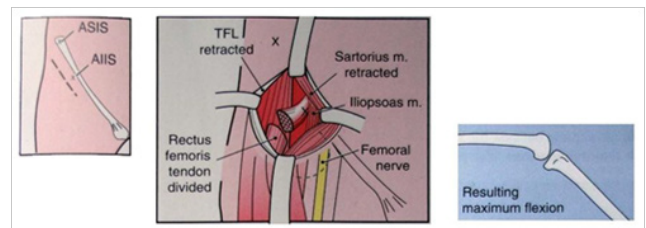


Figure 4 Incisions for Judet quadricepsplasty.

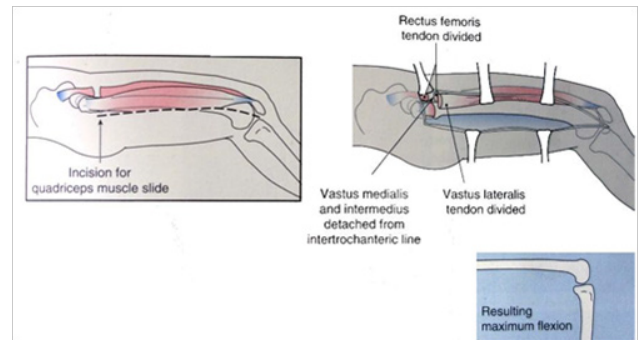


Figure 5 Incisions for Judet quadricepsplasty.

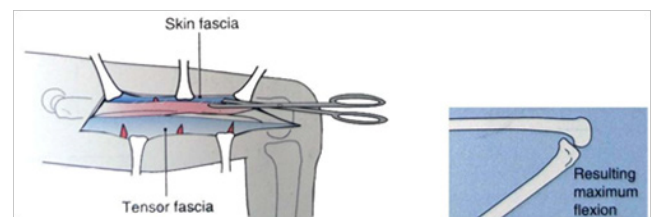


Figure 6 Incisions for Judet quadricepsplasty.

Case illustrations: (Figure 7-13).

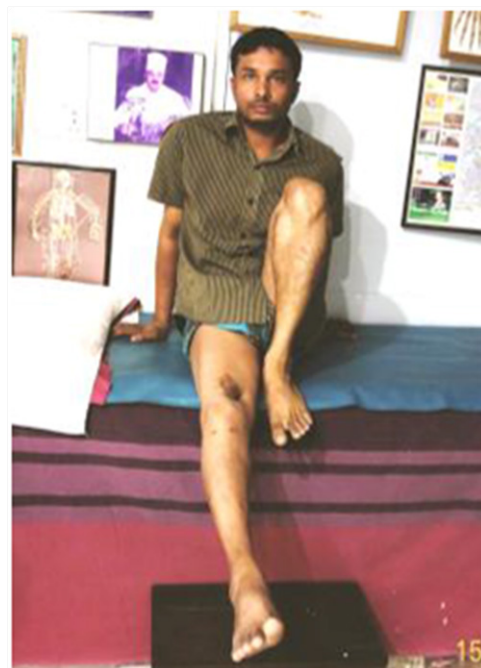

Figure 7 Incisions for Judet quadricepsplasty.

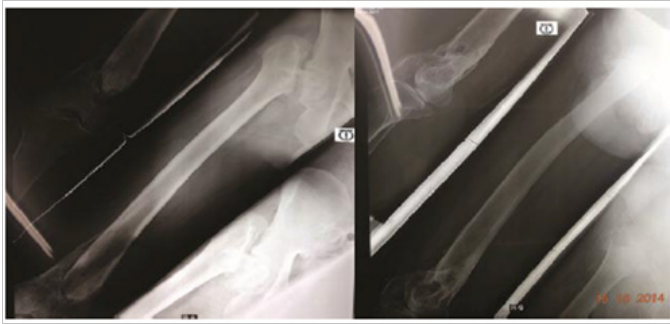

Figure 8 Incisions for Judet quadricepsplasty.

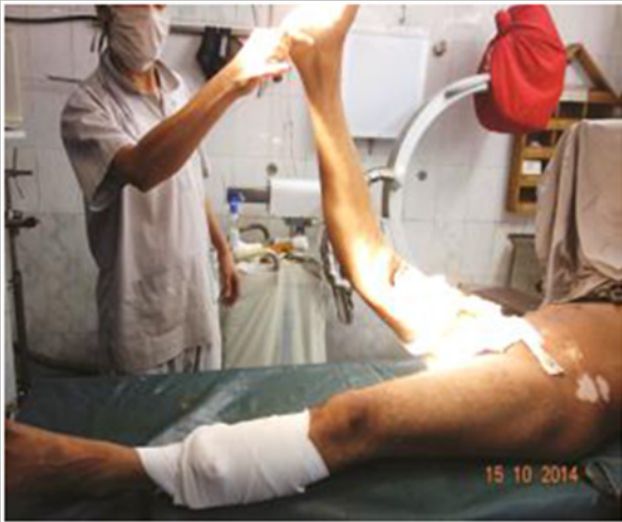

Figure 9 Incisions for Judet quadricepsplasty.

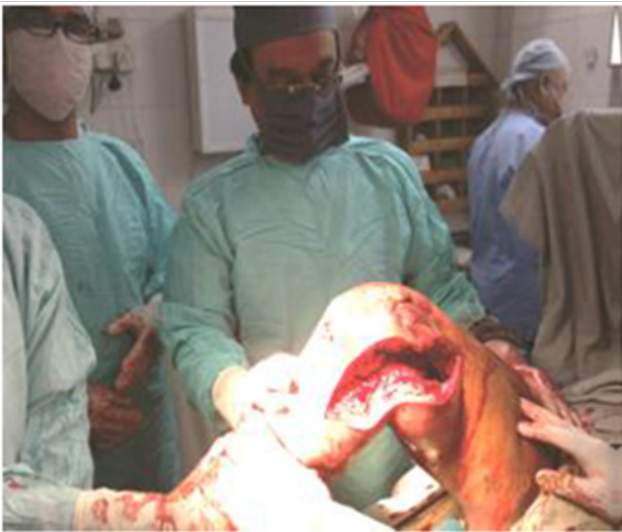

Figure 10 Incisions for Judet quadricepsplasty.

Postoperative care

It is mandatory to do aseptic dressing from day 1. Plaster is removed. The passive knee movement is continued through the whole range obtained at operation was done 3 times a day. We are using CPM machine for exercises from the 3rd postoperative day. We are not worried about the sutures, the skin sutures were retained till 3 to 4 weeks. During discharge the patients were instructed to do exercises in the knee regularly and also to built quadriceps by active physiotherapy.

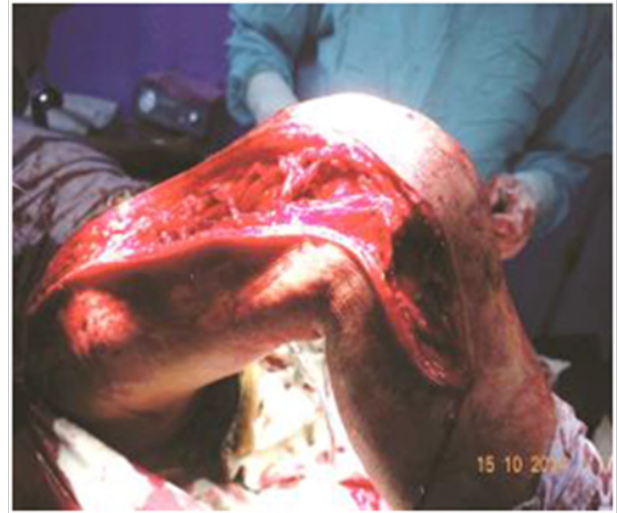

Figure 11 Incisions for Judet quadricepsplasty.

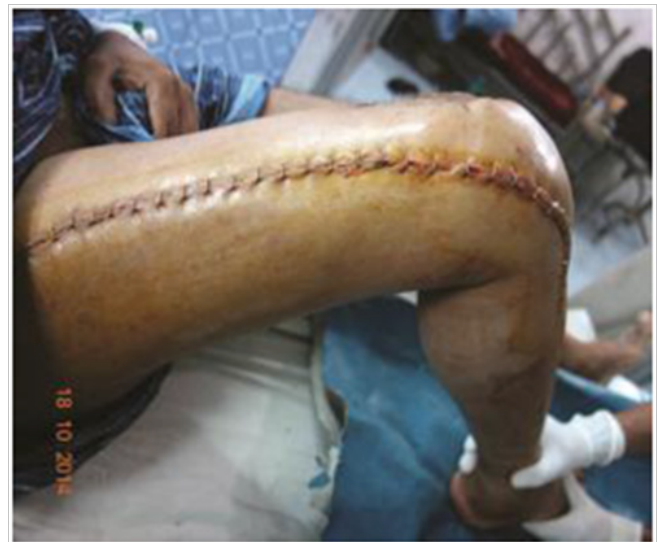

Figure 12 Incisions for Judet quadricepsplasty.



Figure 13 Incisions for Judet quadricepsplasty.

Results

Ilizarov application was the cause of contracture in 12 patients (37.50%) followed by internal fixation for periarticular fractures in 20 patients (62.50%). The degree of flexion increased from 15 degree's (range 10° to 15°) preoperatively to 85 degrees (20° to 150°) on the

last follow up showing a flexion gain of 58 degrees. Mean quadriceps strength at follow up was 5.5 with no extension lag. Wound infection was seen in 6 patients (18.75%). The outcome of our patient according to Judet's criteria on last follow up was excellent in 17 patients (53%), good in 12 patients (37.50%), fair in 2 (6.50%) patients and poor in 1 (3%) patient (Table 1).

Table 1 outcome of our patient according to Judet's criteria

S. No	Pre Operative ROM	Post Operative ROM	Follow Up Period	Final Knee Flexion	Final Outcome
1	15 (0-15°)	115 (0-115°)	10	135°	Excellent
2	15 (0-15°)	120 (0-120°)	8	130°	Excellent
3	10 (0-10°)	115 (0-115°)	6	125°	Excellent
4	15 (0-15°)	110 (0-110°)	7	125°	Excellent
5	18 (0-18°)	110 (0-110°)	5	125°	Excellent
6	18 (0-18°)	110 (0-110°)	2	130°	Excellent
7	15 (0-15°)	110 (0-110°)	3	130°	Excellent
8	15 (0-15°)	110 (0-110°)	4	135°	Excellent
9	10 (0-10°)	110 (0-110°)	5	135°	Excellent
10	10 (0-10°)	110 (0-110°)	6	130°	Excellent
11	15 (0-15°)	110 (0-110°)	7	130°	Excellent
12	15 (0-15°)	110 (0-110°)	10	125°	Excellent
13	10 (0-10°)	110 (0-110°)	2	125°	Excellent
14	20 (0-20°)	110 (0-110°)	3	125°	Excellent
15	20 (0-20°)	110 (0-110°)	4	127°	Excellent
16	15 (0-15°)	110 (0-110°)	5	125°	Excellent
17	15 (0-15°)	80-100°	6	120°	Excellent
18	10 (0-10°)	80-100°	6	90°	Good
19	10 (0-10°)	80-100°	7	90°	Good
20	15 (0-15°)	80-100°	8	85°	Good
21	15 (0-15°)	80-100°	1	80°	Good
22	10 (0-10°)	80-100°	2	82°	Good
23	10 (0-10°)	50-80°	3	80°	Good
24	15 (0-15°)	50-80°	4	86°	Good
25	15 (0-15°)	50-80°	5	80°	Good
26	10 (0-10°)	50-80°	5	85°	Good
27	10 (0-10°)	50-80°	6	85°	Good
28	15 (0-15°)	50°	7	83°	Good
29	15 (0-15°)	50°	8	95°	Good
30	10 (0-10°)	50°	6	75°	Fair
31	10 (0-10°)	50°	7	70°	Fair
32	15 (0-15°)	50°	5	45°	Poor

Discussion

Extension knee contracture is a serious complication after periarticular knee fractures. The components limiting knee flexion have been described by Judet & Nicoll,⁴ including adhesions from the deep surface of patella to the femoral condyles, arthrofibrosis and shortening of vastus medialis, lateralis, intermedius and rectus femoris. With Judet's technique all the vasti are released from the proximal part including the rectus femoris.⁵ We must release the MCL and LCL. In our series we released rectus femoris in all cases to achieve per operative flexion of the knee beyond 90°. We also removed arthrofibrosis from the joint to achieve good range of motion. Skin dehiscence and delayed wound healing was reported by Nicoll BA⁴ and Moore TJ et al.⁵ and as a complication of quadricepsplasty.⁵ But in our series 6 cases developed skin dehiscence and necrosis and delay in wound healing which has got similarity with this study. In this study the skin sutures were retained upto 3 to 4 weeks time postoperatively.⁶⁻⁸ The postoperative care after quadricepsplasty is very important if the flexion is to be maintained without loss of active extension.^{6,9} Exercises with CPM machine and strengthening exercises of the quadriceps must be performed intensively for 6 weeks after the surgery.^{10,11}

Conclusion

Judet's quadricepsplasty for knee extension contracture is a useful procedure to increase the range of motion of rigid knees. It should be performed by experience orthopaedic surgeon with meticulous dissection and followed by physiotherapy with CPM machine. Our results are comparable to what have been reported in international literature.

References

1. Paley D. Principles of deformity correction. Knee extension contracture. Orthopedics, Springer, pp. 2000;563–567.
2. Warner JJ. The Judet quadricepsplasty for management of severe post traumatic extension contracture of the knee; a report of a bilateral case and review of the literature. *Clin Orthop Relat Res.* 1990;256:169–173.
3. Bari MM. A color atlas of limb lengthening, surgical reconstruction and deformity correction by Ilizarov technique. 2013;p. 193.
4. Nicoll EA. Quadricepsplasty. *J Bone Joint Surg Br.* 1963;45:483–490.
5. Moore TJ, Harwin C, Green SA, et al. The results of quadricepsplasty on knee motion following femoral fractures. *J Trauma.* 1987;27(1):49–51.
6. Ikpeme JO. Quadricepsplasty following femoral shaft fractures. *Injury.* 1993;24(2):104–108.
7. Mitra AJ, Makley K, Greer RB. A critical analysis of quadriceps function after femoral shaft fractures in adults. *J Bone Joint Surg Am.* 1990;62(1):61–67.
8. Crawford AJ, Hamblen DL. Outline of Fractures. (10th edn), Churchill Livingstone, Edinburgh, New York, USA, 1992;pp. 468–494.
9. Ebraheim NA, DeTroye RJ, Saddemi SR. Results of Judet quadricepsplasty. *J Orthop Trauma.* 1993;7(4):327–330.
10. Bellemans J, Steenwerckx A, Brabants K, et al. The Judet quadricepsplasty; a retrospective analysis of 16 cases. *Acta Orthop Belg.* 1996;62(2):79–82.
11. Jovanović S, Orlić D, Wertheimer B, et al. Quadricepsplasty after war fractures. *Mil Med.* 2000;165(4):263–267.