

Haemorrhagic Papilledema

Keywords: Papilloedema; Optic disc haemorrhage; Haemorrhagic papilledema; Scotoma; Thrombocytopenia; Raised intracranial pressure

Introduction

A 52-year-old female was referred to Ophthalmology from Haematology complaining of “black flowers over the eyes”. Three weeks previously, she had undergone autologous stem cell transplantation for multiple myeloma. Persistent thrombocytopenia contributed to spontaneous bilateral epidural haematomas managed conservatively with serial platelet transfusions. Visual acuity was 20/20 bilaterally with preserved colour vision and no relative afferent pupillary defect. Slit-lamp biomicroscopy revealed bilateral haemorrhagic papilledema with circumferential peri-papillary nerve fibre layer (flame) haemorrhages (Figure 1 & 2). Foveal encroachment accounted for the patient’s perception of floral scotomas. Deep blot haemorrhages and cotton wools spots are evident. Peripheral platelet count was $15 \times 10^9/L$.

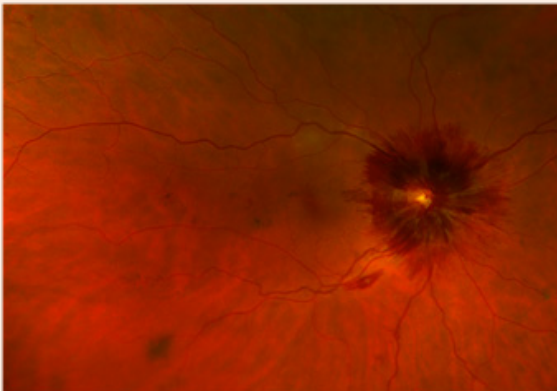


Figure 1: Right eye haemorrhagic papilledema with circumferential peri-papillary nerve fibre layer (flame) haemorrhages.

Discussion

Papilledema results from arrest of axoplasmic transport in retinal ganglion cells that form the optic nerve, at the level of the lamina cribrosa secondary to raised intracranial pressure. Optic disc haemorrhages are a common feature of acute papilledema but may be extensive and symptomatic in the context of thrombocytopenia [1].

Acknowledgement

None.

Clinical Image

Volume 5 Issue 1 - 2018

Imran H Yusuf*, Edward J Ridyard and John S Elston

The Oxford Eye Hospital, West Wing, John Radcliffe Hospital, Headley Way, UK

***Corresponding author:** Imran H Yusuf, The Oxford Eye Hospital, West Wing, John Radcliffe Hospital, Headley Way, Headington, Oxford, OX3 9DU, United Kingdom, Tel: +441865 234736; Email: imranyusuf@doctors.org.uk

Received: December 29, 2017 | **Published:** January 04, 2018

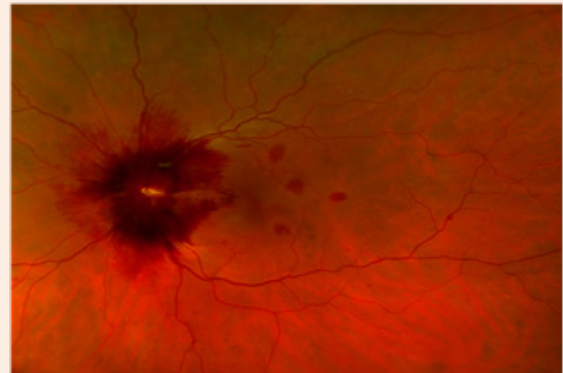


Figure 2: Left eye haemorrhagic papilledema with circumferential peri-papillary nerve fibre layer (flame) haemorrhages.

Conflict of Interest

None of the authors have any financial interest in a product, method or material or lack thereof.

References

1. Abdalla H, Alfshawy M, Babigumira M, Bashir T (2015) Malignant hypertension and thrombotic thrombocytopenic purpura: false friends. *Am J Case Rep* 16: 374-376.