

Intra-Capsular Tonsillotomy by Ultrasonic Method

Forum Article

Volume 9 Issue 4 - 2017

Adnan Qahtan Khalaf^{1*}, Ali Hashoosh Abdullah², Feryal Shakir Taher³ and Emad Malik Abdalrida¹

¹ENT Specialist, Laser Specialist in Otolaryngology, Iraq

²ENT Specialist, Head of ENT Department in Al-Yarmouk teaching hospital/M.O.H., Iraq

³ENT Specialist, Iraq

***Corresponding author:** Adnan Qahtan Khalaf, ENT Specialist, Laser Specialist in Otolaryngology, Al-Yarmouk teaching hospital /M.O.H., Iraq, Tel: +964 770 084 3208; +964 790 1783546; Email: adnan_khtan@yahoo.com

Received: November 26, 2017 | **Published:** December 13, 2017

Abstract

This descriptive prospective study, (non - controlled clinical trial) was conducted during period of February 2016 to February 2017 in AL-Jadryia private hospital total of 80 patients age range (8-64 years old) Gender distribution was 55% male, 45 % female. The patients were compelling from Tonsil hyperplasia, Chronic tonsillitis, Recurrent acute tonsillitis not responding to medical treatment. Surgical Ultrasound (Intra-capsular tonsillotomy) technique was done to them under L.A

Aim of study:

- To evaluate subjective & Objective improvement of using ultra sound volumetric tissue reduction technique (intra-capsular Tonsillotomy) in patient with Chronic Tonsillitis & Tonsillar Hyperplasia.
- Evaluate safety and effectiveness of surgical ultra sound in management of Chronic Tonsillitis and Tonsillar Hyperplasia.

Patient and methods: The patients were compelling from Tonsil hyperplasia, Chronic tonsillitis, Recurrent acute tonsillitis not responding to medical treatment. Surgical Ultrasound tonsillotomy technique was done to them under L.A; the patient was placed in semi sitting position.

Use of 10% xylocaine spray as regional anesthesia for 7 minute. Ultrasound generator until adjusted 44 - 55 intensity. The probe was introduced through tonsillar crypt while the device is activated, probe introduced for few second until the shrinkage has been occurred before leaving out probe, circular movement on entry point to ensure good hemostasis for few second (5-10 sec.) 4-6 entrance in different site of tonsil may be applied according to the size and the shrinkage that had been occurred (A phenomenon known as cavitations).

Results: There is minimal to no bleeding and pain, Slough can be seen in the first week after that disappears, slight shrinkage in the size immediate (intra-operation) but can be seen obvious after 6 weeks, there is subjective improvement in the snoring as per patient partners.

Conclusion: The results suggest that surgical Ultrasound tonsillectomy technique is an efficient & well tolerated procedure for the management of chronic tonsillitis and tonsillar hyperplasia.

Introduction

Today's physicians are paying more attention to enlarged tonsils, realizing that this upper airway obstruction leads to obstructive sleep disordered breathing in children, the cause of a myriad of behavioral and health problems. The conventional treatment for this medical condition is complete removal of the tonsils (total tonsillectomy) by a variety of surgical procedures (cold dissection, electrocautery, microbipolar, and harmonic scalpel). In their search for a less invasive, but equally effective technique, a team of ear, nose, and throat specialists revisited an old procedure, tonsillotomy, or partial tonsillectomy, but in this case, performed with contemporary technology. The procedure involves a reduction in the tonsil size, partially shaving them away using an endoscopic microdebrider, a very small, high-speed device that shaves soft tissue. The partial tonsillectomy eliminates the obstructive portion of the tonsil while preserving the tonsillar capsule. The capsule integrity is maintained, and a natural biologic

dressing is left in place over the pharyngeal muscles, preventing them from injury, inflammation, and infection. The procedure results in less post-operative pain, a more rapid recovery, and perhaps fewer delayed complications [1].

Tonsillotomy is partial Tonsillectomy where eliminate the obstructive portion of Tonsil, while preserving the Tonsillar capsule. The capsule integrity is maintained and natural biologic dressing is left in place over the pharyngeal muscles, preventing them from injury, inflammation and Infection.

Only the medial part of the tonsil is re-moved. It requires that the (well-perfused) lymphatic tissue is resected, and that the remaining crypts remain open to the oropharynx [2,3]. Active lymphatic tissue, with secondary follicles and crypts, is left in the tonsil fossae [4]. Tonsillotomy can be done with most dissecting and coagulating methods. The most common method is laser tonsillotomy and radiofrequency tonsillotomy.

Tonsil hyperplasia

Tonsil hyperplasia, also known as (idiopathic) tonsillar hypertrophy, refers to abnormal enlargement of the palatine tonsil [5,6]. It has to be distinguished from physiological pediatric palatine tonsil hyperplasia [7,8] which is not a sign or consequence of recurrent inflammation [9,10]. Also, children with tonsil hyperplasia do not suffer from acute tonsillitis [11,12] or middle ear infections [13]. A pediatric tonsil is only “pathologically” hyperplastic if snoring (with or without obstructive sleep apnea) or rarely dysphagia [14] or even more rarely dysphonia occur [15].

Grade of tonsillar hyperplasia:

Grade 1: Tonsils hidden within tonsillar pillars.

Grade II: Tonsils, extend the pillars.

Grade III: Tonsils, are beyond the pillars.

Grade IV: Tonsils, extend to midline (Figure 1).

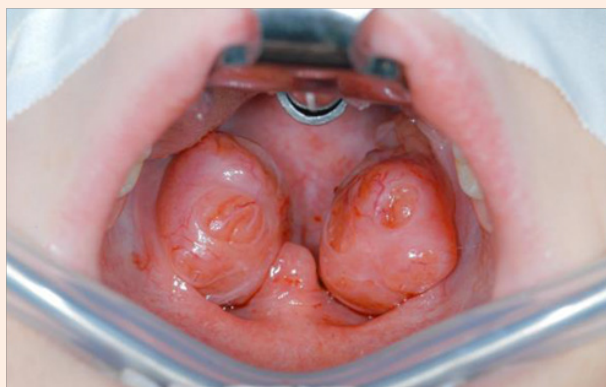

Figure 1: Tonsillar Hyperplasia.

Chronic tonsillitis

Also called “chronic (hyperplastic) tonsillitis”, it is not well-defined and thus should not be used [16]. It is better to speak of (chronic) recurrent tonsillitis [17,18], because true chronic tonsillitis with persistent symptoms lasting >4 weeks with adequate treatment and recovery of the mucosa (as in rhinosinusitis) does not exist.

Recurrent acute tonsillitis

Also called “recurrent tonsillitis” or “recur-rent throat infections” [19], this refers to recur-rent bouts of acute tonsillitis. In contrast to a single attack of acute tonsillitis, it is usually caused by many different bacterial pathogens [20,21] and flare up again a few weeks after cessation of antibiotic therapy [22]. Depending on the frequency and severity of such episodes.

Indications for tonsil surgery

Surgery is done for infections, to relieve air-way obstruction, for halitosis and for diagnosis when a tumor is suspected. Surgery

for recurrent tonsillitis depends on its frequency and severity, and the presence of additional diseases (antibiotic allergies, immunosuppression and PFAPA syndrome).

Paradise criteria for tonsillectomy

Paradise (1984) reported that tonsillectomy significantly lowers the frequency of severe recurrent sore throats in children aged 3-15yrs. Most published guidelines incorporate the so-called Paradise criteria for tonsillectomy:

- i. 7 episodes of tonsillitis per year in one year or,
- ii. 5 episodes of tonsillitis per year in 2 consecutive years or,
- iii. 3 episodes of tonsillitis per year in 3 consecutive years [23].

Techniques of Tonsillectomy

Intracapsular techniques may use the microdebrider, bipolar, radiofrequency ablation (which can also be used to remove the entire tonsil), and carbon dioxide laser. Either extracapsular or intracapsular tonsillectomy can be performed for the pediatric patient with obstructive sleep apnea, but only extracapsular techniques should be used for patients undergoing tonsillectomy as a result of tonsillitis or peritonsillar abscess.

In addition, tonsils can be ablated using a laser or monopolar radiofrequency (somnoplasty). In a cooperative adult in a clinic setting. Harmonic scalpel, Bipolar radiofrequency ablation.

The harmonic scalpel Figure 2 can be used to perform an extracapsular tonsillectomy (Ethicon Endo-Surgery Inc. Cincinnati, OH). It uses ultrasonic energy to vibrate its blade at 55,000 cycles per second. The vibration transfers energy to the tissue, providing simultaneous cutting and coagulation, so, typically, no additional instrument is needed for hemostasis. The components of the device include a generator, a hand piece, and a disposable blade. A high-frequency power supply provides energy to the hand piece. The blade oscillations dissect tissues by creating intra-cellular cavities as pressure waves are conducted through the tissues. The expansion and contraction of these cavities results in the lysis of cellular connections, resulting in tissue dissection (Figure 2).

Indication of tonsillotomy

- i. Tonsillar hyperplasia
- ii. Foetor (halitosis)
- iii. Recurrent detritus (debris) in tonsillar crypt [4].

Surgical Ultrasound

Back ground and physics

Ultrasound energy is a mechanical power, it is not electrical, and the mechanism of separation and detachment of tissue is based on formation of cavities through high frequency vibration which is in conjunction with low pressure at the end of the wave glide cause explosion of cell and tissue separation in various level (A phenomenon known as cavitation's photo destruction effect) [2].

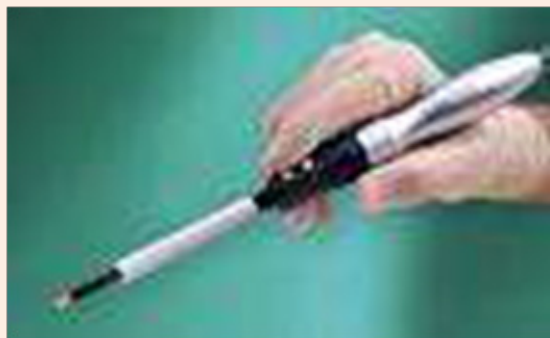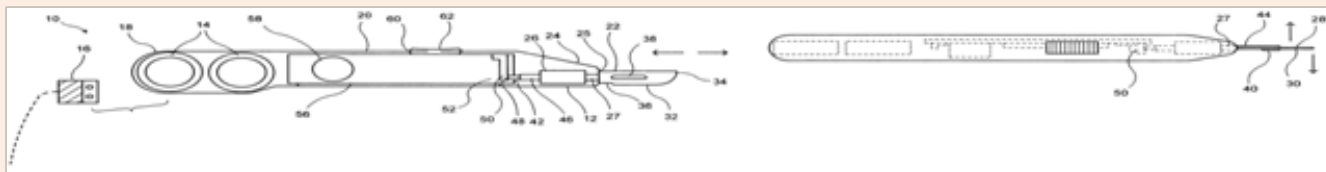


Figure 2: Harmonic/ultrasonic scalpel.

Ultrasound frequency

Ultrasound were discovered in 1880 via the piezoelectric effect A quartz crystal vibrate when it gets to be part of an electrical circle , The frequency of vibrations of the crystal is set by electrical circuit , this crystal vibration second depend on the set value the electrical circuit delivers [2]. In 1920 the first therapeutic use of ultrasound occurred when ultrasound were use to warm muscular tissue [3].

Surgical ultrasound tonsillar tissue reduction: Is a minimally invasive surgical option that can reduce tissue volume in a precise, target with minimal impact on surrounding tissue.

Ultrasound probe is unipolar which insert in the Tonsillar crypt submucosally and induce explosion of cell and tissue separation in various level (A phenomenon known as cavitation).

The advantage of Surgical ultrasound are

- a. The advantage of surgical ultrasound, not electrical
- b. Less postoperative pain / discomfort
- c. Less postoperative risk of bleeding
- d. Minimal damage to adjacent tissue

Patient and Method

This descriptive prospective study, (non - controlled clinical trial) was conducted during period of February 2016 to February 2017 in AL-Jadryia private hospital total of 80 patients age range (8 - 64 years old) Gender distribution was 55% male, 45 % female. The patients where compelling from Tonsil hyperplasia, Chronic tonsillitis, Recurrent acute tonsillitis not responding to medical treatment. Surgical Ultrasound tonsilletomy technique was done to them under L.A. after describing the procedure to the patient and each patient had to sign a consent form.

Inclusion criteria

- a. Age: 8 - 64 years old
- b. Gender: Both sexes
- c. Side: Bilateral tonsillar hypertrophy
- d. Foetor: halitosis
- e. Reconvert detritus (debris) in tonsillar crypts
- f. Patient unfit for surgery.

Exclusion criteria

- a. Patient below age of 8 years
- b. Pregnancy
- c. Bleeding disorder
- d. Uncontrolled D .M.

Procedure

D & A UltraSurge II Device was used in this study (Figure 3).

Table 1 shows the commercial information of the device.

The patient was placed in semi sitting position.

Use of 10% xylocaine spray as regional anesthesia for 7 minute.

Ultrasound generator until adjusted 44 - 55 intensity. As shown in Figure 4.

The probe was introduced through tonsillar crypt while the a devise is activated , probe introduce for few second until the shrinkage has been occurred before leaving out probe , circular movement on entry point to ensure good hemostasis for few second (5-10 sec.)

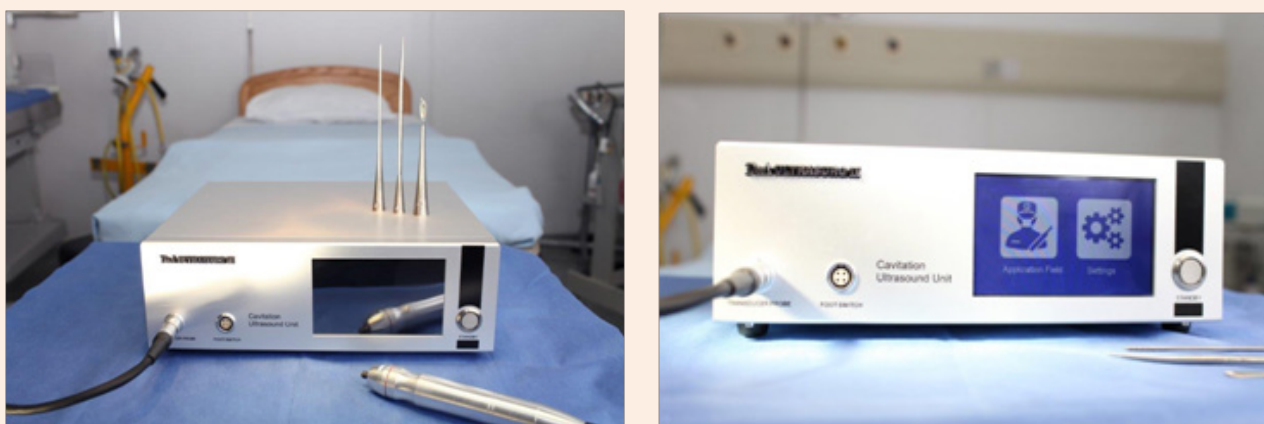


Figure 3: Shows the D&A Ultrasurg Device.

Table 1: Commercial information of D&A ULTRASURG II.

No.	Item Description	Details
1	Dimensions	30 x 27 x 10 cm
2	Generator	4,33 Kg
3	Hand piece – Acoustical transducer	157 gr
4	Electric supply Voltage	230V AC
5	Frequency	50-60 Hz
6	Electric power	max 40W
7	Power Cord	Detachable cable 1,50 m (3×1.5mm)
8	Electrical Safety	Class I, Type B
9	Protection category solid object and water ingress	IP 31
10	Functioning environment temperature	15° - 35°C
11	Relative humidity	30 - 90%
12	Transport and storage conditions	0° - 40°C
13	Unit's operating frequency	48,50 KHz (+ 0,5 KHz)
14	Maximum continuous operation for every operating cycle	400 sec
15	Minimum pause duration needed after maximum continuous operation	200 sec
16	device certification	CE0653

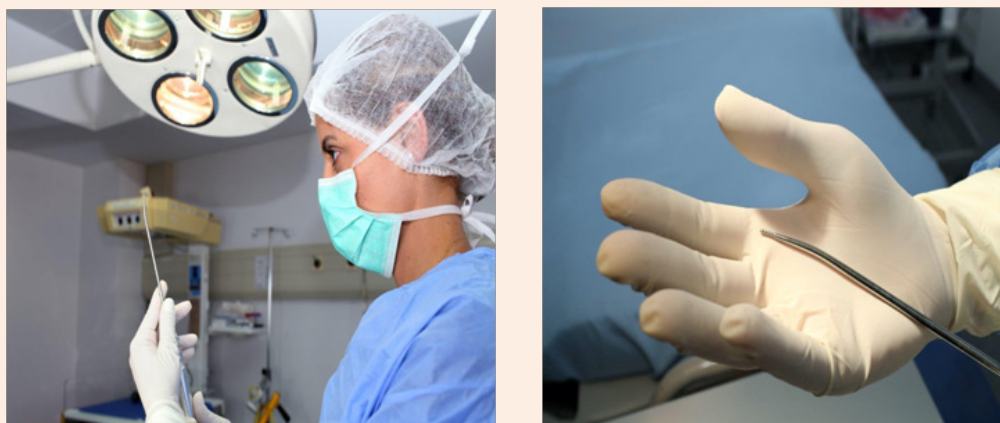


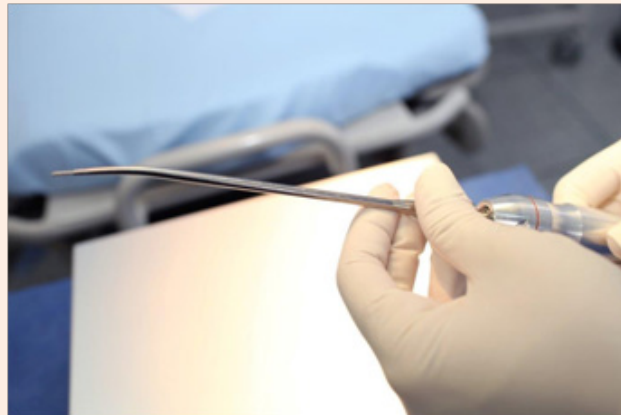
Figure 4: Probe used for Tonsillotomy.

(4-6) entrance in different site of tonsil may applied according to the size and the shrinkage that had been occurred. As show in Figure 4 & 5.

Sterilization of probe was done by immersion of probe in the cidex, also can be done by auto-sterilization by immersion of probe in the N/S for 2 minutes with the activation of the device.



Figure 5: Adjacent of the device.



Mechanism of action

The tonsillar tissue is heated interstitially, subsequent Scarring

cause shrinkage of lymphoid tissue. No tissue is removed and large part of lymphoid allegedly remain function [2], Figure 6.

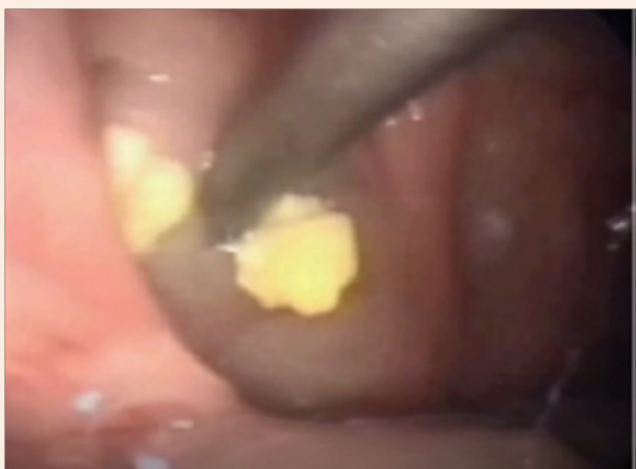
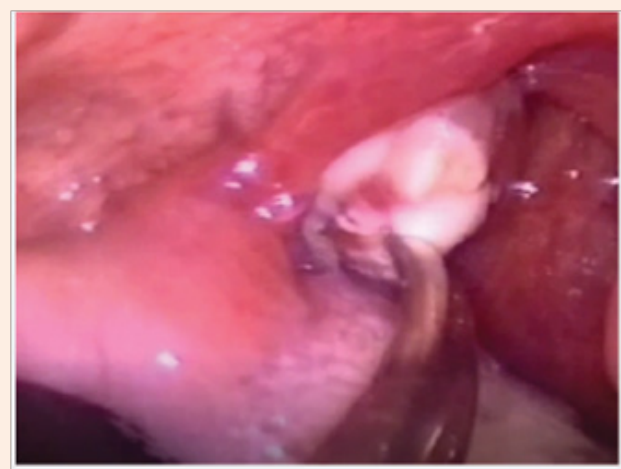
Figure 6: probe inserted in the tonsillar tissue.



Post - operative assessment

The patients were observed for about 1 hour for any bleeding or other complication.

All the patients were discharge home on the following management.

- Acetaminophen (Panadol) 500 mg on need.
- Eating soft cold food on 1st day.
- Advised to follow his or her normal daily activities.
- Augmintin tab

All patients were assessed post - operatively for

Post- operative pain, bleeding 1 st week Grade of Tonsil hypertrophy

Result

Complication during and after surgery, as shown in the tables below, there is minimal to no bleeding and pain, Slough can be seen in the first week after that disappear, slight shrinkage in the size immediate (intra-operation) but can be seen obvious after 6 weeks, there is subjective improvement in the snoring as per patient partners.

Bleeding

Table 2: Bleeding follow-up.

Duration	No.	Description	Percentage %
Intra Operative	4	Oozing	5%
1 st Week	0	No	0%
2 nd Week	0	No	0%

Pain

Table 3: Pain follow-up.

Duration	No.	Description	Percentage %
Intra - Operative	2	Mild	2.5%
1 st Week	10	Sore throat	12.5%
2 nd Week	0	No	0%
One Mouth	0	No	0%

Slough

Immediate white distortions of Tonsillar, after 3 - 4 day slough of tonsillar tissue appear, all of them disappear later (Table 4).

Table 4: Sloughing follow-up.

Duration	No.	Slough	Percentage %
Intra – Operative	60	Mild	75%
1 st Week	40	Mild	50%
2 nd Week	0	No	0%
One Mouth	0	No	0%

Size

About 80% of the patient included in this study shows reduce in the size of the tonsil.

1st post- operative look are one week is mild reduce in size in comparsim to the pre -operative.

There is obvious reduce in size at 3 mouth later (Table 5).

Table 5: Size follow-up.

Duration	No.	Size
Intra – Operative	60	1/5
1 st Week	50	1/5
2 nd Week	40	1/4
One Mouth	40	1/4

Snoring

Both subjective & objective improvement in snoring was observed post – operatively the patient was very satisfy.

Infection and debris

Most of patient did not complain of acute infection in the 1st 6 mouth.

Debris, only 2 of patient had once time recurrent.

Discussion

There is great debate about the relative merits of the various tonsillectomy techniques published in many studies, with many more ongoing that compare the techniques. The existing literature consistently reports that the intracapsular (partial) techniques result in less postoperative pain, however, the degree of lessened pain continues to be much debated [24-26]. In addition; there is a small risk of tonsil regrowth and the necessity for an additional procedure with the intracapsular techniques. Of the extracapsular techniques, “cold” tonsillectomy results in less postoperative pain compared with an electrocautery or “hot” tonsillectomy; however, the latter procedure is typically faster and has less intraoperative blood loss [27].

The equipment involved with various techniques varies in price, although the largest cost factor in any tonsillectomy is the operating time.

Conclusion

Appreciation of the indications and the use of new tonsillectomy techniques and technologies, as well as an awareness of the economic ramifications of their adoption, will ultimately provide the best care for tonsillectomy patients.

The results suggests that surgical Ultrasound tonsillectomy technique is an efficient & well tolerated procedure for the management of chronic tonsillitis and tonsillar hyperplasia.

Acknowledgment

None.

Conflict of Interest

None.

References

- (2002) Partial Tonsillectomy found to be Safer, as Effective, and Less Painful than Complete Removal, Article ID: 31688.
- Scherer H, Fuhrer A, Hopf J (1994) Current status of laser surgery in the area of the soft palate and adjoining regions. *Laryngorhinotologie* 73(1): 14-20.
- Koltai PJ, Solares CA, Mascha EJ, Xu M (2002) Intracapsular partial tonsillectomy for tonsillar hypertrophy in children. *Laryngoscope* 112(8 Pt 2 Suppl 100): 17-19.
- Reichel O, Mayr D, Winterhoff J, de la CR, Hagedorn H, et al. (2007) Tonsillotomy or tonsillectomy?--a prospective study comparing histological and immunological findings in recurrent tonsillitis and tonsillar hyperplasia. *Eur Arch Otorhinolaryngol* 264(3): 277-284.
- Semberova J, Rychly B, Hanzelova J, Jakubikova J (2013) The immune status in situ of recurrent tonsillitis and idiopathic tonsillar hypertrophy. *Bratisl Lek Listy* 114(3): 140-114.

6. Perry M, Whyte A (1998) Immunology of the tonsils. *Immunol Today* 19(9): 414-421.
7. Goldberg S, Shatz A, Picard E, Wexler I, Schwartz S, et al. (2005) Endoscopic findings in children with obstructive sleep apnea: effects of age and hypotonia. *Pediatr Pulmonol* 40(3): 205-210.
8. Reichel O, Mayr D, Winterhoff J, de la CR, Hagedorn H, Berghaus A (2007) Tonsillotomy or tonsillectomy?--a prospective study comparing histological and immunological findings in recurrent tonsillitis and tonsillar hyperplasia. *Eur Arch Otorhinolaryngol* 264(3): 277-284.
9. Ericsson E, Lundeberg I, Hultcrantz E (2009) Child behavior and quality of life before and after tonsillotomy versus tonsillectomy. *Int J Pediatr Otorhinolaryngol* 73(9): 1254-1262.
10. Stelter K, Ihrler S, Siedek V, Patscheider M, Braun T, et al. (2012) 1-year follow-up after radiofrequency tonsillotomy and laser tonsillotomy in children: a prospective, double-blind, clinical study. *Eur Arch Otorhinolaryngol* 269(2): 679-684.
11. Sarny S, Ossimitz G, Habermann W, Stammberger H (2012) The Austrian tonsil study 2010--part 1: statistical overview. *Laryngorhinootologie* 91(1): 16-21.
12. Braun T, Dreher A, Dirr F, Reichel O, Patscheider M (2012) Pediatric OSAS and otitis media with effusion. *HNO* 60(3): 216-219.
13. Gronau S, Fischer Y (2005) Tonsillotomy. *Laryngorhinootologie* 84(9): 685-690.
14. Fischer Y, Gronau S (2005) Identification and evaluation of obstructive sleep apnea in children before adenotonsillectomy using evaluative surveys. *Laryngorhinootologie* 84(2): 121-135.
15. Stuck BA, Gotte K, Windfuhr JP, Genzwurker H, Schrotten H, et al. (2008) Tonsillectomy in children. *Dtsch Arztebl Int* 105(49): 852-860.
16. Burton MJ, Glasziou PP, Chong LY, Venekamp RP (2000) Tonsillectomy versus non-surgical treatment for chronic / recurrent acute tonsillitis. *Cochrane Database Syst Rev* 11: CD001802.
17. Georgalas CC, Tolley NS, Narula A (2007) Recurrent throat infections (tonsillitis). *BMJ Clin Evid*, pii: 0503.
18. Jensen A, Fago-Olsen H, Sorensen CH, Kilian M (2013) Molecular mapping to species level of the tonsillar crypt microbiota associated with health and recurrent tonsillitis. *PLoS One* 8(2): e56418.
19. Swidsinski A, Göktas O, Bessler C, Loening-Baucke V, Hale LP, et al. (2007) Spatial organisation of microbiota in quiescent adenoiditis and tonsillitis. *J Clin Pathol* 60(3): 253-260.
20. Jensen JH, Larsen SB (1991) Treatment of recurrent acute tonsillitis with clindamycin. An alternative to tonsillectomy? *Clin Otolaryngol Allied Sci* 16(5): 498-500.
21. Paradise JL, Bluestone CD, Bachman RZ, Colborn DK, Bernard BS, et al. (1984) Efficacy of tonsillectomy for recurrent throat infection in severely affected children. Results of parallel randomized and nonrandomized clinical trials. *N Engl J Med* 310(11): 674-683.
22. Chan KH, Friedman NR, Allen GC, Yaremchuk K, Wirtschafter A, et al. (2004) Randomized, controlled, multisite study of intracapsular tonsillectomy using low-temperature plasma excision. *Arch Otolaryngol Head Neck Surg* 130(11): 1303-1307.
23. Chang K (2005) Randomized controlled trial of Coblation versus electrocautery tonsillectomy. *Otolaryngol Head Neck Surg* 132(2): 273-280.
24. Hall DJ, Littlefield PD, Birkmire-Peters DP, Holtel MR. (2004) Radiofrequency ablation versus electrocautery in tonsillectomy. *Otolaryngol Head Neck Surg* 130(3): 300-305.
25. Leinbach RF, Markwell SJ, Colliver JA, Lin S (2003) Hot versus cold tonsillectomy: A systematic review of the literature. *Otolaryngol Head Neck Surg* 129(4): 360-364.
26. Hanasono MM, Lalakea ML, Mikulec AA, Shepard KG, Wellis V, et al. (2004) Perioperative steroids in tonsillectomy using electrocautery and sharp dissection techniques. *Arch Otolaryngol Head Neck Surg* 130(8): 917-921.
27. Perkins J, Dahiya R (2003) Microdissection needle tonsillectomy and postoperative pain: A pilot study. *Arch Otolaryngol Head Neck Surg* 129(12): 1285-1288.