

Non-surgical orthodontic treatment of an orthognathic surgical case

Abstract

Introduction: Diagnosis and treatment planning for a skeletal malocclusion that exhibits maxillary retrusion in relation to a prognathic mandible is complex and involves quantification of the skeletal discrepancy while considering the limitations of conventional orthodontic systems. This case report illustrates a highly successful non-surgical orthodontic treatment of an orthognathic surgical case.

Case report: The patient, who is a 32 year old female with a maxillary crossbite and negative overjet, successfully completes non-surgical, non-extraction orthodontic treatment in a little over 12 months. Post-treatment results show a dramatic esthetic improvement, the elimination of a negative overjet and a stable occlusion with good intercuspation.

Conclusion: This case report demonstrates the potential of non-surgical, non-extraction orthodontic therapy for an orthognathic surgical case with a system of braces that utilizes light forces and immediately moves the tooth root (s) to their final position with alveolar bone remodeling and short treatment time.

Keywords: orthognathic surgery, non-extraction orthodontic treatment, mandibular prognathism

Volume 4 Issue 5 - 2016

Anthony D Viazis,¹ Evangelos Viazis,² Tom C Pagonis³

¹Orthodontist, Private Practice, Dallas, Texas, USA

²Private Practice, Athens, Greece

³Assistant Clinical Professor, Department of Restorative Dentistry and Biomaterials Sciences, Harvard School of Dental Medicine, Boston, MA, USA

Correspondence: Tom C Pagonis, Department of Restorative Dentistry and Biomaterials Sciences, Harvard School of Dental Medicine, 188 Longwood Avenue, Boston, MA 02115, USA, Email tom_pagonis@hsdm.harvard.edu

Received: February 07, 2016 | **Published:** July 5, 2016

Introduction

Treatment planning decisions that involve surgical intervention to realign the maxilla and mandible or to reposition dentoalveolar segments in cases of severe malocclusion associated with maxillary retrusion or deficiency and mandibular prognathism are based on the degree of discrepancy and performance limits of conventional orthodontic systems.¹ Clinical presentation of these skeletal and dental asymmetries are considered some of the most complex and difficult to treat and are often most classified as Angle's Class III.² Newer and biologically based diagnostic terminology for this condition is mandibular orthodontosis.³ Patients typically exhibit a prominent lower third of the face which is accompanied by a concave facial profile with a lower lip that is protrusive relative to the upper lip.⁴ While the contribution of oral function and environmental factors are not completely understood, this condition does exhibit a genetic predisposition tendency.⁵⁻⁷ Proper diagnosis of the skeletal case is challenging and requires careful treatment planning. While the patient's chief complaint is most often associated with a poor facial appearance it may be accompanied by functional and temporomandibular problems.⁸

The performance of conventional orthodontic bracket systems limits the clinician's treatment planning choices particularly for cases which typically border surgical intervention. Advances in mechanotherapy and diagnosis now allow the clinician to treatment plan certain skeletal cases with non-extraction orthodontic treatment without surgical intervention.⁹ The following case report illustrates the successful outcome of non-surgical, non-extraction orthodontic treatment of an orthognathic surgical case.

Case report

Diagnosis

The patient is a 32 year-old female who presented to the second author's private practice in Athens, Greece with a chief complaint of great disappointment with her smile and with difficulty chewing (Figure 1). She is apprehensive and admits to dental neglect as a consequence of her facial appearance. On examination the patient has a leptoprosopic facial form, a concave profile with an overbite of 3mm and a reverse overjet of 3 mm. The maxillary dentition with the exception of the maxillary left canine is in crossbite and the patient exhibits defective, discolored restorations. In addition, the maxillary right second premolar, the mandibular left second premolar and first molar are missing with periodontal attachment loss of the mandibular left first premolar.

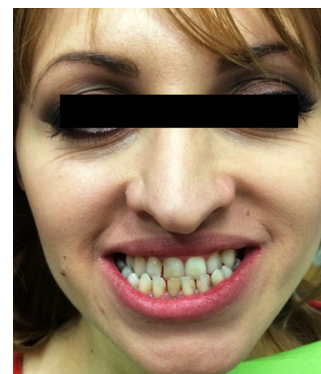

Figure 1A Pre-treatment facial photograph .

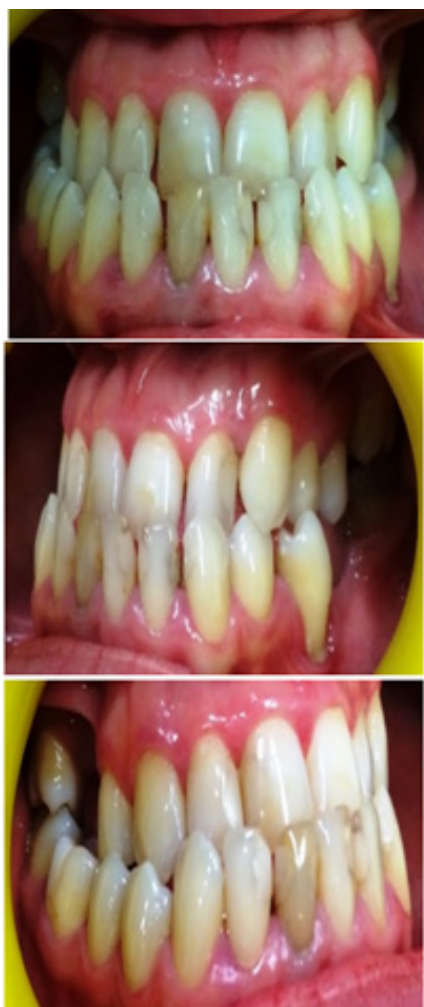

Figure 1B Pre-treatment intra-oral photographs.

Treatment objectives

Upon clinical examination and review of pretreatment panoramic and lateral cephalogram radiographs the patient was informed of both orthodontic and combined orthodontic/orthognathic surgical treatment options and advised of the potentially favorable prognosis of a new non-surgical orthodontic treatment. She decided to pursue non-surgical, non-extraction orthodontic treatment in order to correct her extensive crossbite, obtain proper overjet and overbite relations, level and align her occlusion and restore satisfactory esthetics by utilizing the bracket technology system of Fastbraces® (Figure 2). Periodontal therapy was to be initiated prior to orthodontic treatment with replacement of defective restorations and composite veneers in esthetic areas immediately following orthodontic treatment. Long term treatment goals include prosthetic restoration of the maxillary right and mandibular left quadrants.

Treatment progress

Treatment took a little over 12 months with appointments scheduled approximately on a monthly basis. Brackets were initially placed on the four maxillary incisors for patient comfort for one month. At the second appointment, brackets were placed on all

remaining maxillary teeth and at the third appointment brackets were placed on the mandibular teeth. Interproximal reduction of mandibular teeth in proximal contact was performed and some of the mandibular edentulous spaces were reduced with elastic powers chains.

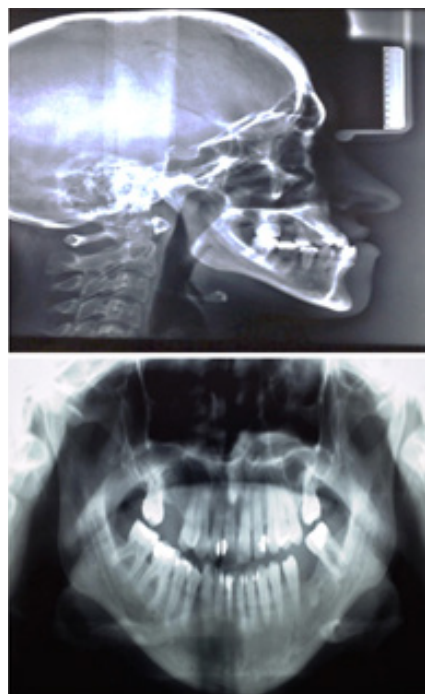

Figure 2 Pre-treatment lateral cephalogram and panoramic radiographs.

Treatment results

Clinical results along with photographs and radiographs comparing pre and post-treatment show dramatic esthetic improvement, non-surgical orthodontic correction of the overbite and a stable occlusion. Edentulous spaces were reduced in preparation for future prosthetic restorations. Overjet and overbite was measured at between 1 to 2 mm with a treatment time of a little over 12 months (Figure 3) & (Figure 4). At a one year follow-up visit the patient maintained stable occlusion with unchanged overjet/overbite relations (Figures 5) and (Figure 6).

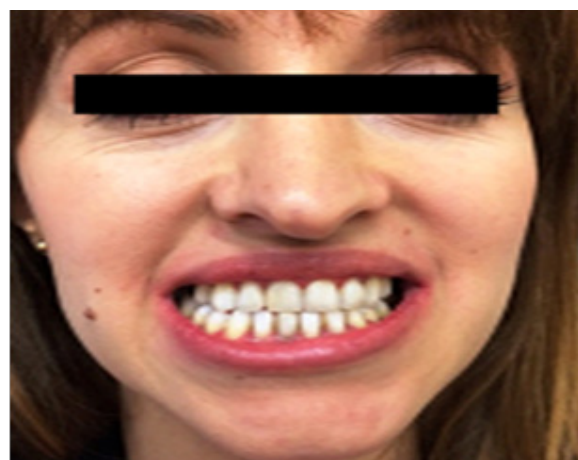

Figure 3A Post-treatment facial photograph.

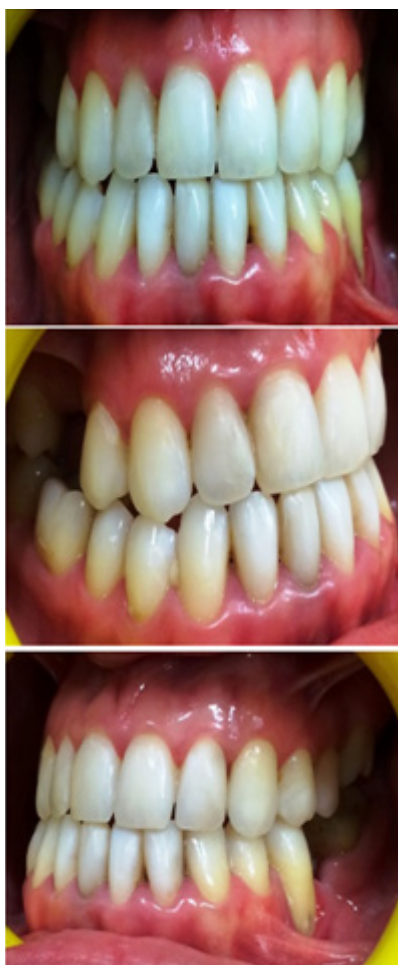

Figure 3B Post-treatment intra-oral photographs.

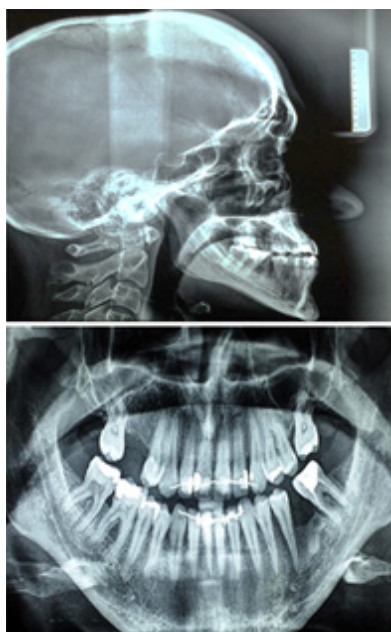


Figure 4 Post-treatment lateral cephalogram and panoramic radiographs.

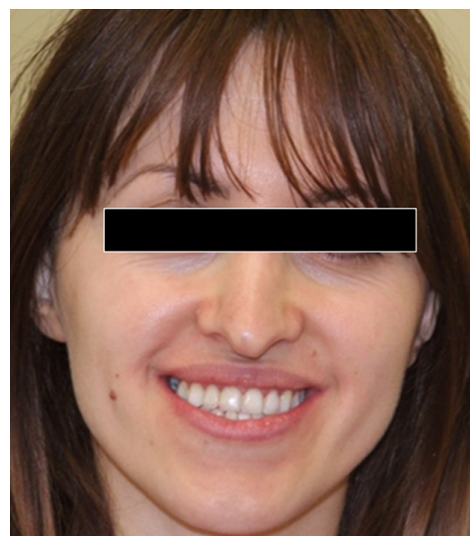

Figure 5A One year post-treatment facial photograph.

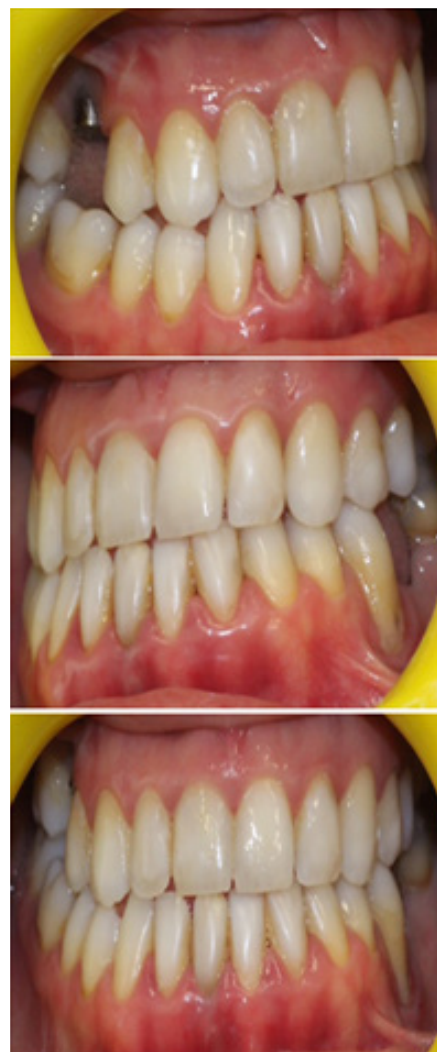

Figure 5B One year post-treatment intra-oral photographs.

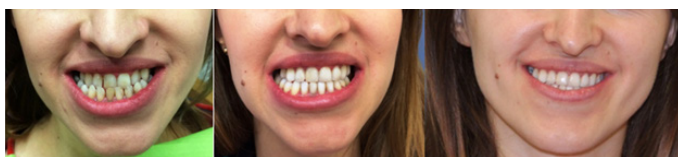

Figure 6 Comparison of pre-treatment, immediate post-treatment and one-year follow-up frontal view photographs.

Discussion

The ultimate goal in treating skeletal malocclusions is to create dentoalveolar changes that correct this imbalance. The strategy for selecting orthodontic treatment or combined orthodontic treatment with surgical orthognathic surgery is usually based on the extent of the anteroposterior and vertical skeletal discrepancy¹⁰ along with the limitations of conventional orthodontic bracket systems. Patients that exhibit significant skeletal discrepancies are often treated with maxillary, mandibular or bimaxillary orthognathic surgical intervention.¹¹ While mandibular orthognathic surgery (i.e. setback surgery) for true or pronounced mandibular prognathism is the treatment of choice, there is still conflicting evidence of its long term stability¹² with reports of up to 33% of cases exhibiting a clinically significant relapse of 2 mm or more.^{13,14} Treatment planning is especially challenging with the borderline orthodontic/orthognathic surgery cases. Patients who forgo the risks and possible complications of surgical intervention for orthodontic treatment with traditional bracket systems frequently undergo multiple dental extractions with a treatment outcome that can be best described as esthetic camouflage since it only partially compensates for a skeletal imbalance.¹⁵

The American Association of Oral and Maxillofacial Surgeons Criteria for Orthognathic Surgery considers a horizontal overjet of 0 to a negative value as medically appropriate for orthognathic surgery.¹⁶ Yet this case report illustrates the dramatic non-surgical correction of maxillary crossbite with a 3 mm negative overjet with the Fastbraces® system. It also illustrates the utilization of this system as a valuable adjunct to the comprehensive dental treatment plan of a complex adult case.

Conclusion

This case report demonstrates the successful non-extraction, non-surgical outcome and correction of a maxillary crossbite accompanied by a negative overjet with Fastbraces®, a new technology system of braces that utilizes light forces and facilitates the continuation of eruption while inducing alveolar bone remodeling and development in short treatment times.³ Carefully diagnosed skeletal malocclusions that are considered borderline orthodontic or orthodontic/orthognathic surgery can potentially be treated orthodontically without extractions and without orthognathic surgery in a timely manner.

References

1. Ishii N, Deguchi T, Hunt NP. Craniofacial difference between Japanese and British Caucasian females with a skeletal class III malocclusion. *Eur J Orthod.* 2002;24(5):493–499.

2. Tellzig-Eisenhauer A, Lux CJ, Schuster G. Treatment decision in adult patients with Class III malocclusion: orthodontic therapy or orthognathic surgery. *Am J Orthod Dentofacial Orthop.* 2002;122(1):27–38.
3. Viazis AD, Viazis E, Pagonis TC. The Concept of a New Dental Disease: Orthodontosis and Orthodontitis. *J Dental Health Oral Disord Therapy.* 2014;1(5).
4. William S, Andersen CE. The morphology of the skeletal potential Class III skeletal pattern in the growing child. *Am J Orthod.* 1986;89(4):302–311.
5. Mossey PA. The heritability of malocclusion: Part 2. The influence of genetics in malocclusion. *Br J Orthod.* 1989;26(3):195–203.
6. Lew KK, Foong WC. Horizontal skeletal typing in an ethnic Chinese population with true class III malocclusion. *Br J Orthod.* 1993;20(1):19–23.
7. Kharbanda OP, Sidhu SS, Sundaram KR. Prevalance of malocclusion and its traits in Delhi children. *J Indian Orthod Soc.* 1995;26:98–103.
8. Proffit WR, Fields HW, Moray LJ. Prevalence of malocclusion and orthodontic treatment need in the United States: Estimates from the NHANES III survey. *Int J Adult Orthodon Orthognath Surg.* 1989;13(2):97–106.
9. Viazis AD, Viazis E, Pagonis TC. The Fallacy of Tongue Thrust and Non-Surgical Treatment of a Severe Anterior Open Bite. *J Dental Health Oral Disord Therapy.* 2016;4(4):00120.
10. Hisano M, Chung CR, Soma K. Nonsurgical correction of skeletal class III malocclusion with lateral shift in an adult. *Am J Orthod Dentofacial Orthop.* 2007;131(6):797–804.
11. Mackay F, Jones JA, Thompson R, et al. Craniofacial form in Class III cases. *Br J Orthod.* 1992;19(1):15–20.
12. Mobark, K, Krogstad O, Espeland L, et al. Long-term stability of mandibular setback surgery: a follow-up of 80 bilateral sagittal split osteotomy patients. *The International Journal of Adult Orthodontics and Orthognathic Surgery.* 2000;15(2):83–95.
13. Bailey L, Cevidanes L, Proffit WR. Stability and predictability of orthognathic surgery. *Am J Orthod Dentofacial Orthop Sep.* 2004;126(3):273–277.
14. Ingervall B, Thuer U, Vuillemin T. Stability and effect on the soft tissue profile of mandibular setback with sagittal split osteotomy and rigid fixation. *Int J Adult rthod Orthognath Surg.* 1995;10(1):15–25.
15. Costa Pinho TM, Ustrell Torrent JM, Correia Pinto JG. Orthodontic camouflage in the case of a skeletal class III malocclusion. *World journal of orthodontics.* 2004;5(3):213–223.
16. AAOMS Parameters of Care: Clinical Practice Guidelines for Oral and Maxillofacial Surgery. Criteria for Orthognathic Surgery. 2005.