

Isolation of *Salmonella typhi* from Perinephric Abscess - A Case Report from National Medical Hospital, Karachi

Abstract

Salmonella typhi is a versatile pathogen with amazing potential of infecting almost all organs of its host. Globally, the life threatening illnesses caused by *Salmonella typhi* have made this pathogen a serious health concern for infection control professionals. Various microbes have been found associated with intrarenal abscesses that ultimately lead to high morbidity and mortality rates. We are reporting an unusual and rare case of intrarenal abscess caused by *Salmonella typhi* in a febrile patient admitted to private care hospital in Karachi. Interestingly, the isolated strain was found to be resistant against first line of drugs but showed intermediate pattern towards ciprofloxacin.

Keywords: *Salmonella typhi*; Perinephric abscess; Antibiotic resistance; Meningitis; Empyema

Case Report

Volume 3 Issue 4 - 2016

Samiya Kainat* and Naila Tariq

Department of Microbiology, National Medical Centre, Pakistan

***Corresponding author:** Samiya Kainat, Clinical Microbiologist, Department of Microbiology, National Medical Centre, Karachi, Pakistan, Email: samiyakainat@gmail.com

Received: September 22, 2016 | **Published:** December 30, 2016

Introduction

Salmonella typhi are non-capsular, non-spore forming, non-lactose fermenting, gram-negative motile rods [1]. Enteric fever is subsequent to intestinal manifestation caused by *Salmonella typhi* in humans [2]. However the organism is also found associated with rare extra intestinal illnesses such as, meningitis, endocarditis, liver abscess, myocarditis, empyema and urinary tract infection, etc [3-6]. Globally *Salmonella typhi* still remains a major health concern that annually is responsible for approximately 27 million cases [7]. Asian countries including Pakistan, India and Bangladesh account for most of these intestinal and non-intestinal cases. Pakistan belongs to the high rate typhoidal endemic regions.

Perinephric abscess is the presence of purulent exudate in perinephric spaces. The chances of true diagnosis are occasionally rare. A wide range of microorganisms have been reported in literature that is responsible for causing high morbidity and mortality in intrarenal abscess. Species of *Staphylococci*, *Klebsiella*, *Pseudomonas*, *Proteus*, *Salmonella paratyphi A* and *Escherichia coli* are among the frequently isolated pathogen from perinephric abscess [7,8].

Our report is from Microbiology unit of National Medical Centre, showing an interestingly rare clinical presentation of perinephric abscess caused by *Salmonella typhi* with its antibiotic susceptibility pattern. The isolate was resistant to first line of drugs (ampicillin, chloramphenicol, nalidixic acid and cotrimoxazole) and sensitive to third generation cephalosporin. The isolate has shown increased minimum inhibitory concentration for fluoroquinolone.

Case Presentation

A 30-years old female was admitted to the National Medical Center with the history of persisting fever, headache, weakness, abdominal pain and loss of appetite since last 3 months. A week before arrival to the hospital, she was taking anti tuberculosis

treatment (ATT), as prescribed by a local doctor without any actual diagnosis. The consultant after examining patient sent request for blood and urine culture, CBC, liver function tests, urea, creatinine, electrolytes, chest x-ray, ultrasound whole abdomen to the clinical laboratory and radiology department of the hospital respectively. Intravenous fluid infusion and panadol (to manage pain) were given initially to the patient until the investigation results revealed. The blood picture showed 7.9 g/dl (Hb), 424,000 mm³ (PLT) and 7,100 mm³ (WBC) respectively. The renal profile showed urea 10mg/dl and creatinine 0.5mg/dl while liver function tests were found to be within normal ranges. Chest x-ray showed no active lesion excluding pulmonary tuberculosis. The whole abdomen ultrasound showed normal liver, spleen, pancreas, gall bladder, urinary bladder, whereas the right kidney which was of normal size, shape and place. Figure 1A Echogenicity of renal cortex was seen as normal. Corticomedullary distinction was seen intact. But the left kidney was found enlarged (11.9 x 5.5) with perinephric abscess. There was well defined hypoechoic lesion of 6.5 x 3.6 cm noted in upper pole of left kidney extending outside the kidney and filled with thick level echoes inside. Doppler showed no significant flow (Figures 1B & 1C).

On the basis of these clinical findings, the ultrasound guided aspiration was planned and performed under aseptic measures and approximately 50 cc of thick pus aspirated from left perinephric abscess. The pus specimen was sent to microbiology laboratory for culture and sensitivity, AFB smear and AFB culture. The gram stain of the exudate showed few gram negative rods with numerous pus cells. The AFB smear was negative. The non-lactose fermenting gram negative *bacilli* were isolated from culture that was further processed for identification and antibiotic sensitivity testing. The GNBS were identified as *Salmonella typhi* on conventional biochemical reactions. The isolate was further confirmed by performing serotyping (remel). The isolate was resistant to ampicillin (10µg, oxid), chloramphenicol (30µg, oxid), nalidixic acid (30µg, oxid) and co-trimoxazole

(1.25/23.75µg, oxoid) but interestingly intermediate sensitivity was show to ciprofloxacin (MIC = 0.12µg/ml, oxoid). Ceftriaxone (30µg, oxoid), cefoperazone-sulbactam (105µg, oxoid) were found to be sensitive. No organism was reported from urine culture and blood culture. Widal test was performed from the stored serum sample. The test was found positive with the titer of 1:320 against *Salmonella typhi* flagellar (H) and somatic (O) antigens.

The patient was given intravenous treatment with cefoperazone-sulbactam (1g) twice a day. The symptoms subsided and the patient was discharged on third day of hospitalization with the advice of continuing treatment for 2 more days. The patient showed no symptoms on her follow-up visits to the hospital. Later the AFB culture report was also negative.

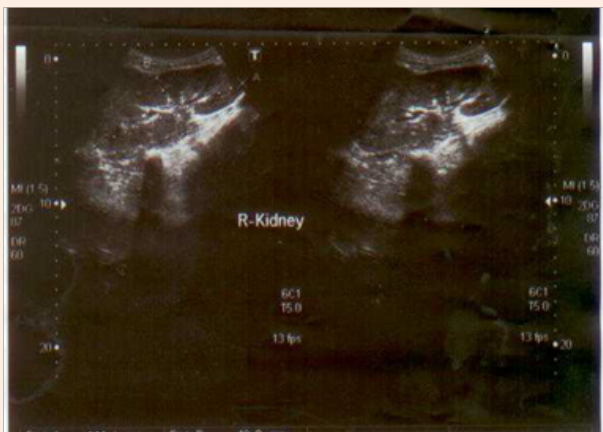


Figure 1A: Ultrasound showing.

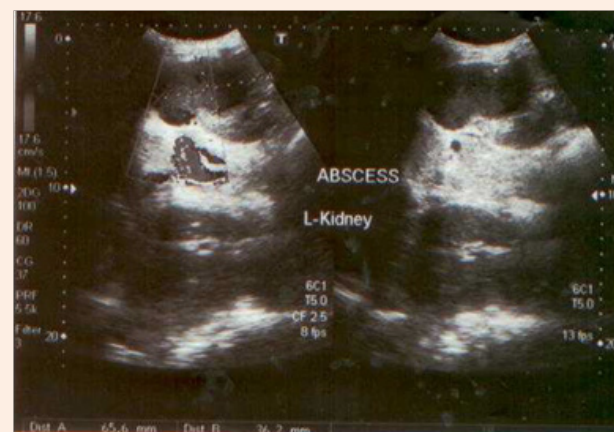

Figure 1B: Normal right kidney.

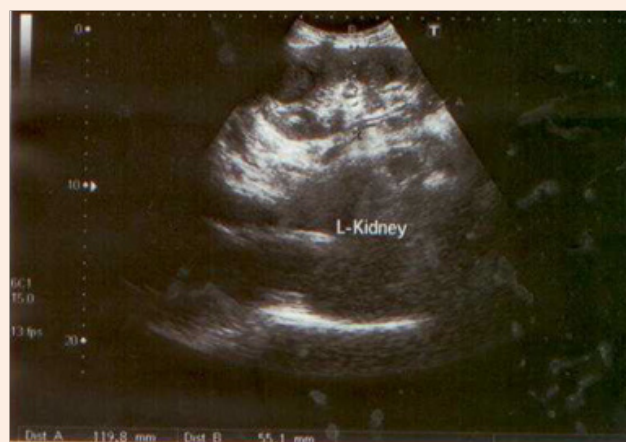

Figure 1C: Perinephric abscess in left kidney.

Discussion

Salmonella typhi is responsible for causing typhoid fever [1,2]. The typhoid epidemic and endemics is still a therapeutic challenge for developing countries due to their poor sanitary management, health hygiene and unavailability of drinkable water and food [7,8]. In contrast, the ability of *Salmonella typhi* to produce unusual and rare clinical manifestations always forces clinician to keep this pathogen in mind for actual diagnosis of an infection [9]. There are reports available on the pathogenesis of perinephric/intrarenal abscess by *Salmonella paratyphi A*, *Salmonella virchow*, *Salmonella enteritidis* and *Salmonella Typhimurium* [10,11].

However, there are very few reports available on the involvement of *Salmonella typhi* in intrarenal abscess. Our report is a rare clinical presentation of perinephric abscess caused by *Salmonella typhi*. The isolate was interestingly intermediate to ciprofloxacin (MIC = 0.12µg/ ml, oxoid) but sensitive to 3rd generation cephalosporin.

Intrarenal abscess leads to high mortality and morbidity rates if not treated accurately. As far as treatment of perinephric abscess is concerned it is crucial to drain the purulent material along with appropriate antibiotics. Fluoroquinolones has been the therapeutic drug of choice for Salmonellosis, however worldwide

reports on increasing antibiotic resistance of *Salmonella typhi* isolates are also creating an alarming situation [12,13]. This rare presentation of *Salmonella species* is of great significance as it provided awareness to our healthcare consultants regarding potential risk of this pathogen to infect almost all vital organs of its host.

Acknowledgement

The authors have taken a written consent from the patient for the publication of this case report.

The authors acknowledge the efforts of all the medical laboratory staff of National Medical Centre for their assistance. The authors also show gratitude to Prof. Dr. Aqeel Ahmad, Chairman, Department of Microbiology, University of Karachi, Pakistan, for his guidance.

References

1. Ugboko H, De N (2014) Mechanisms of Antibiotic resistance in *Salmonella typhi*. *Int J Curr Microbiol App Sci* 3(12): 461-476.
2. Kaur A, Sarma S, Kumar N, Sengupta S (2015) Renal abscess caused by *Salmonella Typhi*. *J Lab Physicians* 7(2): 121-123.
3. Dravid M, Joshi BN (1990) Renal abscess due to *Salmonella typhimurium*. *Indian J Pediatr* 57(4): 586-588.
4. Afridi FI, Farooqi BJ, Hussain A (2012) Pleural empyema due to *Salmonella typhi*. *J Coll Physicians Surg Pak* 22(12): 803-805.
5. Aslam F, Bhaila I, Nadeem N, Fadoo Z (2005) *Salmonella typhi*-infected lung hydatid cyst. *Pediatr Infect Dis J* 24(3): 270-272.
6. D'Cruz S, Kochhar S, Chauhan S, Gupta V (2009) Isolation of *Salmonella paratyphi A* from renal abscess. *Indian J Pathol Microbiol* 52(1): 117-119.
7. Crump JA, Mintz ED (2010) Global trends in typhoid and paratyphoid Fever. *Clin Infect Dis* 50(2): 241-246.
8. Cabral JPS (2010) Water Microbiology. *Bacterial Pathogens and Water*. *Int J Environ Res Public Health* 7(10): 3657-3703.
9. Hashino S, Imamura M, Tanaka J, Noto S, Kobayashi S, et al. (1996) Renal *Salmonella enteritidis* abscess in a patient with severe aplastic anemia after allogeneic stem cell transplantation. *Bone Marrow Transplant* 18(4): 807-808.
10. Chinh NT, Parry CM, Ly NT, Ha HD, Thong MX, et al. (2000) A randomized controlled comparison of azithromycin and ofloxacin for treatment of multidrug-resistant or nalidixic acid-resistant enteric fever. *Antimicrob Agents Chemother* 44(7): 1855-1859.
11. Bassily S, Farid Z, Barsoum RS, Soliman LA, Higashi GI, et al. (1976) Renal biopsy in Schistosoma-Salmonella associated nephrotic syndrome. *J Trop Med Hyg* 79(11): 256-258.
12. Renuka K, Kapil A, Kabra SK, Wig N, Das BK, et al. (2004) Reduced susceptibility to ciprofloxacin and gyrA gene mutation in North Indian strains of *Salmonella enterica* serotype typhi and serotype paratyphi A. *Microb Drug Resist* 10(2): 146-153.
13. White NJ, Parry CM (1996) The treatment of typhoid fever. *Curr Opin Infect Dis* 9: 298-302.