MedCrave
Step into the World of Research
Journal of Anesthesia & Critical Care: Open Access

Review Article
Open Access
CrossMark

Thoracic spinal anesthesia

Abstract

In 1909 Thomas Jonnesco published his interesting paper under the title ***General spinal anesthesia*** through an approach of the subarachnoid space at a thoracic level, providing condition for surgery on the skull, head, neck and thorax. Etherington-Wilson proposed explaining the various possibilities for the spinal anesthesia. Leonardo da Vinci was considered the discoverer of Human and animal Anatomy. Image techniques have opened a gret new field for the study of anatomy in the living man. The modern means of image, associated to computed means have facilitated the evaluation of the CSF volume, through antero-posterior and height measures of the subarachnoid space based on bi-dimentional studies of MRI. The studies of the thoracic column with MRI show that exist a space between the dura-mater and the spinal cord (medula). Thoracic ouncture performed with needles proved safe and without neurological injury. Thoracic spinal anesthesia is a viable procedure, with a low incidence of hypotension and did not present any neurologic problem.

Volume 4 Issue 5 - 2016

Luiz Eduardo Imbelloni,[1,2,3] Marildo A Gouveia[4]

[1]Doctor of Anesthesiology Faculty of Medicine of Botucatu, São Paulo, Brazil
2Professor of School of Medicine Nova Esperança, João Pessoa, Brazil
3Anesthesiologist Complexo Hospital Mangabeira, Brazil
[4]Director of Institute of Regional Anesthesia, Brazil

Correspondence: Luiz Eduardo Imbelloni, Doctor of Anesthesiology Faculty of Medicine of Botucatu, São Paulo, Professor of School of Medicine Nova Esperança, João Pessoa, Anesthesiologist Complexo Hospital Mangabeira, Rua Marieta Steimbach Silva, 101/1001, Miramar, 58043-320 – João Pessoa, Brazil, Email dr.imbellon@terra.com.br

Received: March 30, 2016 | **Published:** April 25, 2016

History

Until the year 1913, oral surgery, neck surgery and maxilofacial procedures were all made under inhalational anesthesia with a face mask, mucosal soaking of local anesthetic, rectal anesthesia, venous anesthesia or total spinal anesthesia. None of these techniques would protect the airway. In the oder hand it puts the patient prone to aspirate blood or mucous secretion to the lungs. It was in that year that Chevalier Jackson related the high success rate of protection of the airway with the tracheal intubation technique.[1]

In November 1909 Thomas Jonnesco published his interesting paper under the title ***General spinal anesthesia*** through an approach of the subarachnoid space at a thoracic level, providing condition for surgery on the skull, head, neck and thorax.[2] He proposed two sites in the thoracic spine to approach the subarachnoid space: the high thoracic site and the low thoracic site. The high thoracic approach should be between the first and second thoracic vertebra that would provide a deep and perfect analgesia for the higher segment of the body (head, neck, upper members). The lower approach should be done between the 12th thoracic and 1st lumbar vertebra that would be easily recognized and would provide anesthesia for the lower segment of the body. Jonnesco thought that the midpoint thoracic approach was more difficult to be done and unnecessary as the higher segment (T1-T2 approach) or as the lower segment (T12-L1). In the following years the work of Jonnesco was criticised for two times. The first one in 1910[3] with 18 patients the author finishes his paper saying that *"spinal anesthesia is not yet recognized as a field of anesthesia"* and a second in 1911[4] that is an Editorial in wich complication of local anesthetic are discussed instead of anesthetic techniques.

In 1932, Kirschner[5] described the technique for segmental spinal anesthesia, approaching the subarachnoid space with the patient in the lateral position and head up. He aspirated spinal fluid and injected air. Used hypobaric solution of nupercaine. Vehrs[6] provided segmental thoracic anesthesia through a high approach.

In 1934[7] and 1935[8] Etherington-Wilson, in two papers, proposed some explanations for the block of spinal roots intratechally, explaining the various possibilities for the spinal anesthesia, through a *glass spinal canal*. Two years later, using the method proposed by Etherington-Wilson in 200 patients, the authors perceived that analgesia extended until the higher segments of the thorax, and proposed the segmental spinal anesthesia.[9] In 1942, based in these new concepts, spinal anesthesia for thoracic surgery was proposed.[10] At that time, thoracic surgery was a difficult task. In 1954, Frumin and col[11] also used segmental thoracic spinal through the lumbar apporach inserting a radio-opaque cateter in the subarachnoid space until the 12th thoracic vertebra.

Cadaver anatomy?

In the middle age, Leonardo da Vinci was considered the discoverer of Human and animal Anatomy. He dissected over 20 cadavers in the School of Medicine, describing the vertebral column[12] anatomical concepts that remain up to date in what it concerns the cadaver. Still in the cadaver he observed that the dura-mater was pushed forward by the needle producing a tent, and that stall protect the spinal pia mater during spinal puncture preventing spinal cord injury.[13] The tent of the dura-mater and the risk of lesion are greater with the 18-G than with the 22-G.[13]

Anatomy through image

Image techniques such as radiography, angiogaphy, computerized axial tomography, Magnetic Ressonance Image (MRI), Angiography, Echography, Termography have opened a gret new field for the study of anatomy in the living man. The MRI is the new technique that permits to determine the properties of a substance through a correlations of absorbed energy with the applied frequency. Formerly, the supine position was mandatory for its administration. With technological improvent, it can now be applied in the standing patient, in the supine position or in a slanting position,[9] what permits not only the evaluation and visualizations of the thoracic subarachnoid space in angles never seen before, but also promisses new anatomical knowledge in the living man.

The MRI has been recognized because of its promissing use in the healthy patient or with CNS disease.[14] The rootlets of the *cauda*

equina have been exaustively studied using this technique. The radiculae produce a patern resambling a crescent moon[15] spreading diffusely and filling the posterior aspect of the lumbar subarachnoid space.[16,17] Three papers on MRI present excelent information on the anatomy of the thoracic vertebral canal.[18–20]

The modern means of image, associated to computed means have facilitated the evaluation of the CSF volume, through antero-posterior and height measures of the subarachnoid space based on bi-dimentional studies of MRI.[21]

Anatomy studies about the medular cone has demonstrated that the *cauda equina* has a dinamic attitude that varies with the position assumed by the patient.[22,23] So, bending the column forward facilitates the introduction of the needle into the subarachnoid space in the lumbar segment not providing protection to the medulla.[22] The spinal medula and the cauda equina move inside the canal, depending on the gravity, when the patient assumes lateral decubitus, occurring it in all its extension, being it greater at L2-L3 with a mean movement of 3.4±1.0 mm.[23] In the inferior thoracic segment the deviation was of only 1.0 mm.[23] Forced flexion of the spine moves the spinal cord and cauda equina anteriorly (ventrally) while the forced flexion of the limbs provides the forward movement of the whole medula anteriorly.[23]

Accidental perforation of the dura mater during thoracic epidural block

Accidental perforiation of the dura-mater during epidural attempts may happen with an incidence that varies according with to the hability of the professional and the carachteristics of the patient, and it may vary between 0.4% to 4.4% in a series of 6,496 cases, and no patient of the 48 cases with perforation developed neurological sequelae.[24–27] An anatomical explanation for the lack of damage was proposed by Imbelloni and Gouveia (Figure 1).[28,29] In the printed MNR the following measures where found: 5.19 mm in T_2, 7.75 mm in T_5 and 5.88 mm in T_{10}, or let us say, suficient distance to permit the careful advancement of a needle (accidentally of intenionally) without reaching the medula and administer anesthetic for a segmental spinal anesthesia.

Cervical and thoracic myelography

Myelography under subarachnoid approach in the cervical and thoracic segments was practiced before the advancement of Computerized Tomography and Magnetic Nuclear Ressonance. In 1990 a study involving 220 neuroradiologists with 187,300 mielografies in wich the approach was realized between C_1 and C_2.[30] In this study, 68 compications were detected, what represents 0.023% of all mielographies practiced in this approach, being 63% of them as a consequence of hiperextension of the vertebral column during the procedure.[30] The study demostrated that eventually an *eletric schock* can be felt. The study demostrated that eventually the observed eletric shock may be provoked by the touch of the needle in the spinal cord or any rootlet during lateral approach in the cervical segments C_1 and C_2. But no case of permanent lesion,[30] but a few cases of transitory paresia due to the contact of the needle in the medulla.[31]

An *enquete*, among 351 members of the American Society of Neuroradiology, confirmed that mielography in the cervical and thoracic segments is considered safe and continue indicated in some clinical situations.[32] Studying the cervical and thoracic column through MRI it is evident that the spinal cord is adhered posteriorly in the cevical region and anteiorly in the thoracic segment.[20] The lateral approach between C1 and C2 is point of choice for mielography. This choice can be understood by the presence of a pool of CSF posteriorly and the spinal cord anteriorly. The lateral approach prevents the medula from being touched by the needle. Correcting the distance between the dura-mater and the medula one can see an increase in the distance by the angle of entrance, what reduces the possibility of neurological lesion during the acidental perforation of the dura-mater.

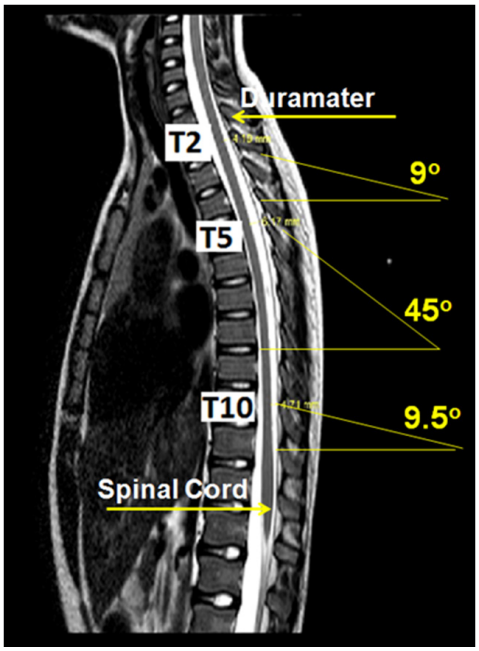

Figure 1 Magnetic Ressonance Image.

Thoracic approach

It is importante to understand the anatomy when performingneuraxial blocks in the toracic segment. When the subarachnoid space is approached through a combined spinal-epidural technique, the piercing of dura by the needle is easily felt. The straigt alignement of the spinous processes favours the identification of the level of approach to the epidural or subarachnoid space in the midline. The angled position of the spinal processes of the thoracic vertebra makes it difficult. In a general way the paramedian approach favors the piercing of the needle and the introduction of a cateter in the thoraxic epidural level.[33] The same way, the knowledge of the depth between the skin and the epidural space through the paramedian access helps the identification of the entry local of the needle in this space.

The evaluation of the subarachnoid space with the patient in the supine position has shown that the distance between the dura-mater and the spinal cord in the thoracic segment is greater in the midthoracic point than cephalad or cauddad.[20] Neuraxial blocks are realized with the patient in the lateral position or seated. This way it is less likely that the positioning of a patient determines the great moving of the tissius of such a closed space. Although the dura-mater may displace along the vertebral canal,[34] only small moviments of adipose tissue and blood pooling may affect the width of the measures evaluated.[35,36] On top of the thoracic curve the spinal cord is kep steady by the denticulate ligament, being that in this localization it stays anteriorly. With the knowledge of the anatomy of the thoracic column recently evaluated,[20] it is expected that the patient in dorsal decubitus or in the sitting position the exagerated curvature of the column may displace the spinal cord more anteriorly, what would reduce the risk of damage of the neural tisssue by the needle of the anesthesist.

Toracic spinal

In 1909 Jonnesco used to give thoracic spinal anesthesia with great hability, describing the best space, the best needle (cutting point), making believe that it would not be necessary an approach higher than $T_{10.}$[2] In that time anatomy was little known as phisiology and the quality of the drugs of nowadays did not exist, let alone tracheal intubation.

It is well known that anesthesiogists frequently fail to identify a vertebral space. In a study trying to localize the L_3-L_4 interspace the incidence of correct answer was of only 29%.[37] Because of this possibility, we have to admit that in many opportunities one may think he (she) is giving a lumbar block when they are effectively giving a thoracic block. The studies of the thoracic column with MRI[18–20] show that exist a space between the dura-mater and the spinal cord (medula). Van Zundert[38,39] and Imbelloni[40] have placed segmental spinal anesthesia through a combined spinal-epidural technique in a combined spinal-epidural block via a thoracic approach and produced segmental spinal anesthesia using a set of combined spinal epidural block and a thoracic approach without any complication.

This study was important for the thoracic spinal anesthesia as it demonstrated the incidence of complication and mainly the paresthesia when comparing lumbar and thoracic approach. In 300 patients submitted to thoracic approach comparing needles of cutting point and pencil point, divided acording with the position of approach (sitting and lateral position) cutting point needle and pencil point needles were used. It was shown that the incidence or paresthesia was 6.6% (4.67% cutting) vs 8.67% (pencil point).[41] The incidence of 6.6% was almost half of what was found in an experience of lumbar puncture (12%) that was used to calculate the size of the sample.[42] All patients were followed for 30 day and and no sequel or complication was detected.

Spinal anesthesia is commonly used for a large range of procedures. It presents the advantage of a simple technique, safe and efective, producing a deep block. On the other way, anesthesiologists are reluctant in considering the possibility of toracic spinal anesthesia, fearing a trauma to the cord. The majority of anesthesiologists give thoracic epidural blocks that eventually perforate the dura and that depends of knowledge, hability, attention and a variety of other factors. Recently, one anatomical explanation was proposed to explain the absence of neuurologic complicationsduring acidental dura perforation.[28] The *Thoraco-abdominal Nerve Block* book suggests that spinal anesthesia may be placed deliberately in the thoracic level.[43]

Advantages of thoracic spinal anesthesia

Spinal anesthesia is comonly used en a variety or surgical procedures. It presents the advantage of a good muscle relaxation, in a conscious patient and a fast post-operative recovery. Minor doses reduce the gravity and incidence of hypotension during the block. Another advantage in relation to the conventional dosis is the faster recovery time (shorter motor blck – longer sensory block).

Recently, studying 646 patients submited to spinal thoracic anesthesia under a low approach confirmed the results of Jonnesco,[2] in 1909, that thoracic spinal anesthesia is a viable procedure, with a low incidence of hypotension and did not present any neurologic problem.[44]

The total amount of CSF in the thoracic segment is less in comparison to the lumbar and cervical segment,[21] and the toracic radiculae are thinner as compared to the lower or upper ones.[36] So, there is a lesser dilution of the anesthetic per segmento f the distance of the site of injection, and the rootles as easily blocked due to its small diameter, both factors of good block. Other important point is the onset time with isobaric solution in the lumbar segment that is longer than with the hyperbaric solution. When the injection is given in the thoracic segment the difference is not significant between the solutions.[44]

Comparing conventional dosis of hiperbaric bupivacaine and lumbar puncture with half the dose in the thoracic injection the onset time is reduced to reach $T_{3.}$[44] The duration of motor and sensory block, incidence of hypotension and capability to move themselves to the transport cart (stretcher) were significantly shorter with the smaller dose and thoracic approach.[44]

Conclusion

If the thoracic epidural reamain as a safe technic, even with the possibility of an accidental perforation of the dura-mater, the anatomical explanation that prevents a cord lesion (the distance between the dura-mater and the cord) suggest that spinal anesthesia may be used with the same safety. In 1909 Jonnesco described all that we now know about the possibility of a thoracic spinal. An important book of regional anesthesia suggest that thoracic subarachnoid block can be preformed deliberately. Thoracic spinal anesthesia may be placed with half the dose used in the lumbar region, reducing colateral effects. The same way, the use of hyperbaric solutions and a light Trendelenburg position reinforces the spread of the solutions in the posterior canal (sensitive rootlets) with shorter durations of motor block and a longer sensitive block. This reflects a lesser incidence of hypotension, shorter durations of motor block, and a longer time of pos-operative anlagesia.

Acknowledgments

None.

Conflicts of interest

Author declare that there is no conflict of interest.

Funding

None.

References

1. Jackson C. The technique of insertion of intratracheal insufflation tubes. *Surg Gynecology Obstetrics*. 1913;17:507–509.
2. Jonnesco T. General spinal analgesia. *Br Med J.* 1909;2(2550):1396–1401.
3. McGavin L. Remarks on eighteen cases of spinal analgesia by the stovaine–strychnine methods of Jonnesco, including six cases of high dorsal puncture. *Br Med J.* 1910;2(2954):733–736.
4. Jonnesco AN. Spinal anesthesia. Journal of Medicine, California, USA;1911. p. 401–402.
5. Kirschner M. Spinal zone anesthesia, placed at will and individually graded. *Surg Gynec Obst*. 1932;55:317–329.
6. Vehrs JR. Spinal Anesthesia. Mosby Co., St. Louis, USA; 1934.
7. Etherington–Wilson W. Intrathecal nerve root block. Some contributions and a new technique. *Proc R Soc Med.* 1934;27(4):323–331.
8. Etherington–Wilson W. Intra–thecal nerve rootlet block. Some contributions: A new technique. *Anesth Analg. 1935*;14:102–110.

9. Bourne W, O'Shaughnessy PE. The Etherington–Wilson technique in intrathecal segmental analgesia. *Can Med Assoc J.* 1936;35(5):536–540.

10. Bourne W, Leigh MD, Inglis AN, et al. Spinal anesthesia for thoracic surgery. *Anesthesiology*. 1942;3:272–281.

11. Frumin MJ, Schwartz H, Burns J, et al. Dorsal root ganglion blockade during threshold segmental spinal anesthesia in man. *J Pharm Exp Ther.* 1954;112(3):387–392.

12. Zöllner F. Leonardo da Vinci. Obra Completa de Pintura e Desenho. Taschen; 2003.

13. Orrison WW, Eldevik, Sackett JF. Lateral C1–2 puncture for cervical myelography. Part lll:Historical, anatomic and technical considerations. *Radiology*. 1983;146(2):401–408.

14. Hornak JP. The Basics of MRI. Interactive Learning Software, Henietta, New York, USA; 2010.

15. Naidich TP, King DG, Moran CJ, et al. Computed tomography of the lumbar thecal sac. *J Comput Assist Tomogr.* 1980;4(1):37–41.

16. Monajati A, Wayne WS, Rauschining W, et al. MR of the cauda equina. *AJNR Am J Neuroradiol*. 1987;8(5):893–900.

17. Ross JS, Masaryk TJ, Modic MT, et al. MR imaging of lumbar arachnoiditis. *AJR Am J Roentgenol.* 1987;149(5):1025–1032.

18. Imbelloni LE, Ferraz–Filho JR, Quirici MB, et al. Magnetic resonance imaging of the spinal column (Letter to Editor). *Br J Anaesth.* 2008;101(3):433–434.

19. Lee RA, van Zundert AAJ, Breedveld P, et al. The anatomy of the thoracic spinal canal investigated with magnetic resonance imaging (MRI). *Acta Anaesth Belg.* 2007;58(3):163–167.

20. Imbelloni LE, Quirici MB, Ferraz–Filho JR, et al. (2010) The anatomy of the thoracic spinal canal investigated with magnetic resonance imaging. Anesth Analg 110(5):1494–1495.

21. Hogan QH, Prost R, Kulier A, Taylor ML, Li S, et al. Magnetic resonance imaging of cerebrospinal fluid volume and the influence of body habitus and abdominal pressure. *Anesthesiology.* 1996;84(6):1341–1349.

22. Fettes PDW, Leslie K, McNabb S, et al. Effect of spinal flexion on the conus medullaris:a case series using magnetic resonance imaging. *Anaesthesia*. 2006;61(6):521–523.

23. Takiguchi T, Yamaguchi S, Tezuka M, et al. Measurement of shift of the cauda equine in the subarachnoid space by changing position. *Reg Anesth Pain Med*. 2009;34(4):326–329.

24. Leão DG. Peridural torácica:estudo retrospectivo em 1240 casos. *Rev Bras Anestesiol*. 1997;47:138–147.

25. de Bessa PRN, Costa VV, Arci ECP, et al. Thoracic epidural block performed safely in anesthetized patients. A study of a series of cases. *Rev Bras Anestesiol*. 2008;58(4):354–362.

26. Scherer R, Schmutzler M, Giebler R, et al. Complications related to thoracic epidural analgesia:a prospective study in 1071 surgical patients. *Acta Anaesthesiol Scand.* 1993;37(4):370–374.

27. Giebler RM, Scherer RU, Peters J. Incidence of neurologic complications related to thoracic epidural catheterization . *Anesthesiology*. 1997;86(1):55–63.

28. Imbelloni LE, Gouveia MA. Low incidence of neurologic complication during thoracic epidural. Anatomic explanation. *Am J NeuroRadiology*. 2010;31(10):E84.

29. Robertson HJ, Smith RD. Cervical myelography:Survey of modes of practice and major complications. *Radiology*. 1990;174(1):79–83.

30. Heinz ER, Goldman RL. The role of gas myelography in neuroadiologic diagnosis. Comments on a new and simple technique. *Radiology*. 1972;102(3):629–634.

31. Mullan S, Harper PV, Hekmatpanah J, et al. Percutaneous interruption of spinal–pain tracts by means of strontium90 needle. *J Neurosurg.* 1963;20:931–939.

32. Sandow BA, Donnal JF. Myelography complications and current practice patterns. *AJR Am J Roentgenol*. 2005;185(3):768–771.

33. Cousins MJ, Veering BT. Epidural neural blockade. In: Cousins MJ & Bridenbaugh PO, editors. Neural blockade in clinical anesthesia and management of pain. Lippincott–Raven Publishers, Philadelphia, USA; 1998. p. 243–321.

34. Takiguchi T, Yamaguchi S, Hashizume Y, et al. Movement of the cauda equine during the lateral decubitus position with fully flexed leg. *Anesthesiology*. 2004;101(5):1250.

35. Takiguchi T, Yamaguchi S, Okuda Y, et al. Deviation of the cauda equine by changing position. *Anesthesiology*. 2004;100(3):754–755.

36. Hogan Q. Size of human lower thoracic and lumbosacral nerve roots. *Anesthesiology*. 1996;85(1):37–42.

37. Broadbent CR, Mascwell WB, Ferrie R, et al. Ability of anaesthetists to identify a marked lumbar interspace. *Anaesthesia*. 2000;55(11):1122–1126.

38. van Zundert AAJ, Stultiens G, Jakimowicz JJ, et al. Segmental spinal anaesthesia for cholecystectomy in a patient with severe lung disease. *Br J Anaesth*. 2006;96(4):464–466.

39. van Zundert AAJ, Stultiens G, Jakimowicz JJ, Peek D, et al. Laparoscopic cholecystectomy under segmental thoracic spinal anaesthesia:a feasibility study. *Br J Anaesth*. 2007;98(5):682–686.

40. Imbelloni LE, Fornasari M, Fialho JC. Combined spinal epidural anesthesia during colon surgery in a high–risk patient. Case Report. *Rev Bras Anestesiol*. 2009;59(6):741–745.

41. Imbelloni LE, Pitombo PF, Ganem EM. The Incidence of paresthesia and neurologic complications after lower spinal thoracic puncture with cut needle compared to pencil point needle. Study in 300 Patients. *J Anesth Clinic Res*. 2010;1:106.

42. Hopkinson JM, Samaan AK, Russel IF, et al. A comparative multicentre trial of spinal needles for Caesarean section. *Anaesthesia*. 1997;52(10):1005–1011.

43. Katz J, Renck H. Handbook of thoraco–abdominal nerve block. In:Grune & Straton, editors. INC, Switzerland; 1987. p. 102.

44. Imbelloni LE, Sant'Anna R, Fornasari M, et al. Laparoscopic cholecystectomy under spinal anesthesia. A comparative study between conventional dose and low dose of hyperbaric bupivacaine. *Local Reg Anesth.* 2011;4:41–46.