

# The Results of Anterior Transposition of the Inferior Oblique: Anterior Fibres Sutured to Sclera Versus Bunch-Up Technique

## Abstract

**Purpose:** To evaluate the results of 2 different surgical techniques of anterior transposition of the inferior oblique (IOAT) in patients with dissociated vertical deviation (DVD): anterior fibres sutured to sclera versus bunch-up technique.

**Methods:** 121 patients were included: group 1: In 41 patients (82 eyes) only the anterior fibers of the IO adjacent were placed to the temporal corner of the inferior rectus insertion; group 2: In 80 patients (160 eyes), the anterior and posterior fibers were bunch-up and sutured near the temporal corner of the inferior rectus insertion.

**Results:** The DVD values were measured and calculated for right eye/left eye (RE/LE) in prism dioptres (PD). Group 1: The values of DVD decreased from pre-operative RE/LE 8, 82/8, 36 PD to a post-operative of RE/LE 1, 33/1, 13 PD. None of the patient had limitation of elevation. Group 2: The values of DVD decreased from pre-operative values of RE/LE 12, 98/10, 67 PD to RE/LE 3, 47/2, 18 PD post-operatives.

a. When  $DVD \leq 15$  PD, DVD.

Group 1: from pre-operative RE/LE 8, 08/7, 72 PD to post-operative RE/LE 1, 44/0, 77 PD.

Group 2: from pre-operative RE/LE 10, 90/10, 16 PD to post-operative RE/LE 1, 84/1, 41 PD.

b. When  $DVD > 15$  PD

Group 1: from pre-operative RE/LE 20/10 PD to post-operative RE/LE 10/0 PD.

Group 2: from pre-operative RE/LE 20/20 PD to post-operative RE/LE 6/6 PD.

In patients from group 2, limitation of elevation in abduction followed, mild in 34 and moderate in 9 patients, 2 had anti-elevation syndrome (AHS).

**Conclusion:** IOAT with only anterior fibers of the inferior oblique sutured to sclera is a safe and effective procedure for DVD correction, especially when  $DVD \leq 15$  PD. The bunch-up technique may cause limitation of elevation and AHS.

## Research Article

Volume 6 Issue 2 - 2017

**Luminita Teodorescu\* and IA Velcea**

*Department of Paediatric Ophthalmology, Oftalmix SOP  
Ophthalmology Clinic, Romania*

**\*Corresponding author:** Luminita Teodorescu, Oftalmix SOP, Ophthalmology Clinic, Bucharest, Romania  
Str Turturelelor, nr 11 B, bl A, ap A03-A04 Sector 3,  
Bucuresti, Romania, Tel: 0722 500935; 0734 994494; 031  
4259440; Fax: 031 4259440; Email:  
luminita.teodorescu@oftalmix.ro

**Received:** December 12, 2016 | **Published:** February 08, 2017

**Abbreviations:** IOAT: Anterior Transposition of the Inferior Oblique; DVD: Dissociated Vertical Deviation; PD: Prism Dioptres; RE: Right Eye; LE: Left Eye; AHS: Anti-elevation Syndrome; DSC: Dissociated Strabismus Complex; IO: Oblique Muscle; SR: Rectus Muscle; IR: Inferior Rectus; AES: Anti-elevation Syndrome

## Introduction

Dissociated strabismus complex (DSC) includes dissociated horizontal, vertical, torsional deviation, latent nystagmus and sub-normal binocularity [1]. It is usually bilateral but asymmetric; may manifest spontaneously or with cover testing. As clinical manifestation, DSC is a comitant drift of both eyes: the fixating eye manifests depression, adduction and intorsion and the non-fixating eye manifests elevation, abduction and extorsion to compensate for the drift of the fixating eye. A reversal of these

movements is seen with refixation [2,3]. The upward vertical version is produced mostly by the inferior oblique muscle (IO) of the fixing eye and the superior rectus muscle (SR) of the non-fixing eye [3].

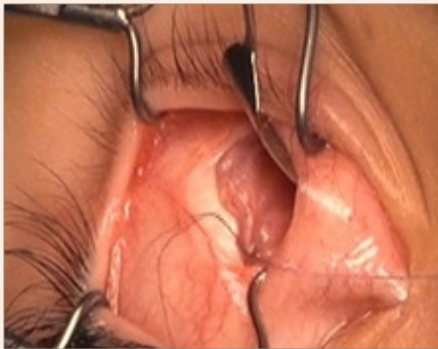
The surgical options for DVD correction are:

- IO anterior transposition (IOAT) in DVD with IOOA (inferior oblique over action) – for treatment of both DVD and IOOA.
- SR recession in DVD without IOOA: symmetrical, bilateral and large.
- Inferior rectus (IR) resection in residual DVD.
- In V pattern with IOOA: anterior and nasal transposition of the inferior oblique (IO).

- v. In A pattern with SOOA (superior oblique over action): SR recession and SO posterior tenectomy or 4 oblique muscles weakening procedure.
- vi. Horizontal muscle surgery when horizontal deviation or DHD co-exist.

## Methods

The surgical technique of IOAT had changed over time. The reason for using IOAT in DVD is that in up-gaze, contraction of the transposed IO limits elevation and the IO muscle is converted from an elevator into a depressor [4]. First the “spread out technique” was used; the insertion of the IO was spread out concentric with limbus. This new insertion created a “J deformity” [4], and anti-elevation syndrome (AES) occurred frequently with extorsion in up-gaze [5]. Then the “bunch up technique” was used, bunching together the anterior and posterior fibers of the IO. This technique was also followed by AES in long term follow-up. In the new technique only the anterior fibers of IO were sutured to the temporal corner of the IR insertion (Figure 1).



**Figure 1:** Anterior fibers of IO sutured near the temporal corner of the IR insertion.

The study included 121 patients with DVD operated in our clinic between 2000 and 2013. Group 1 included 41 patients (82 eyes), mean age 59, 72 months (10-178 months), follow up 4, 21 (4-10 months). Only the anterior fibers of the IO adjacent were placed near the temporal corner of the inferior rectus insertion. Group 2 included 80 patients (160 eyes). The anterior and posterior fibers were bunch-up and sutured near the temporal corner of the inferior rectus insertion. The posterior fibers were kept 3 mm posterior to IR insertion in order to avoid “J” deformity [6]. In both groups, bilateral symmetric IOAT was done in all cases, irrespective of DVD asymmetry. Horizontal muscle surgery was added when necessary: in 103 patients for esotropia, 8 patients for exotropia, 10 patients had no horizontal strabismus and only IOAT was done.

## Results

The DVD values were measured and calculated for right eye/left eye (RE/LE) in prism dioptres (PD). Group 1: The values of DVD decreased from pre-operative RE/LE 8, 82/8, 36 PD to a post-operative of RE/LE 1, 33/1, 13 PD. None of the patient had limitation of elevation.

Group 2: The values of DVD decreased from pre-operative values of RE/LE 12, 98/10, 67 PD to RE/LE 3, 47/2, 18 PD post-operatives.

- a. When  $DVD \leq 15$  PD, DVD.

Group1: from pre-operative RE/LE 8, 08/7, 72 PD to post-operative RE/LE 1, 44/0, 77 PD.

Group 2: from pre-operative RE/LE 10, 90/10, 16 PD to post-operative RE/LE 1,84/1, 41 PD.

- b. When  $DVD > 15$  PD

Group1: from pre-operative RE/LE 20/10 PD to post-operative RE/LE 10/0 PD.

Group 2: from pre-operative RE/LE 20/20 PD to post-operative RE/LE 6/6 PD.

In patients from group 2, limitation of elevation in abduction followed, mild in 34 and moderate in 9 patients, 2 had antielvation syndrome (AHS). Residual DVD may result after IOAT using either of these 2 techniques. 10 from 80 patients from group 2 (12, 1 %) required re-operations for residual DVD. Similar results were obtained by other authors [7,8] (Table 1).

## Discussion

The risk of AHS increases after lateral placement of the posterior fibers [9]. Placing the posterior fibers further temporal to the Y axis may cause substantial extorsion with Y or T pattern [10]. Anti-elevation in abduction following IOAT can be caused by extorsion [11]. The risk of AHS increases also after IOAT with IO resection [12]. In order to avoid AHS, in group1, the posterior fibers were freely left hanged back. In all our patients surgery was bilateral and symmetrical and IO was placed at the IR insertion. Few of the reasons were that although DVD and IOOA may be observed unilaterally, but after unilateral surgery DVD or IOOA may become prominent in the other eye. Also, unilateral IOAT can result in lower lid asymmetry.


## Conclusion

Our results suggested that IOAT with only the anterior fibers of the IO sutured to sclera is a safe and effective procedure for DVD correction, with no postoperative hypotropia or elevation deficit. We prefer to use this technique when  $DVD \leq 15$  PD because is effective, without having the risk of AES. When pre-operative  $DVD > 15$  PD we use the IOAT “bunch-up” technique only in very asymmetrical DVD cases, IOAT “bunch-up” technique in the eye with larger DVD and anterior fibers IOAT in the other eye. We use to perform moderate bilateral SR recession 6-7 mm as a second procedure for residual DVD, We are aware about the limitations of this study: group 1 is much smaller than group 2, in group 1 the follow-up is shorter (4-10 versus 4-156 months); there are only 2 patients from group 1 with pre-operative  $DVD > 15$  PD.

**Table 1:** Results of surgery in DVD using IOAT- AF in group 1 and IOAT-bunch technique in group 2.

Pts: Patients; DVD: Dissociated Vertical Deviation; PD: Prism Dioptres; IOAT- AF: Only the Anterior Fibers of the IO Adjacent were Placed near the Temporal Corner of the inferior Rectus Insertion; IOAT-bunch: The Anterior and Posterior Fibers were Bunch-up and Sutured Near the Temporal Corner of the Inferior Rectus Insertion with the Posterior Fibers was kept 3 mm Posterior to IR Insertion; AES: Antielevation Syndrome.

|  | Group 1  | Group 2   |
|--|--|---|
| Number of pts  | 41 (82 eyes)   | 80 (160 eyes)   |
| Age (in months)  | 10-178<br>mean age 59, 72  | 17-228<br>Mean age 64,60  |
| Follow-up (in months)  | 4-10 months<br>mean 4,21   | 4-156<br>Mean 31,25   |
| Surgical technique   | IOAT- AF   | IOAT-bunch  |
| DVD<br>Preoperative OD/OS/Asymmetry<br>(Minimum, maximum)<br>Postoperative OD/OS/Asymmetry<br>(Minimum, maximum) | 8,82/8,36/0,46<br>(min 0, max 20)<br>1,33/1,13/0,29<br>(min 0, max 18) | 12,98/10,67/2,31<br>(min 0-max 25)<br>3,47/2,18/1,29<br>(min 0, max 18) |
| DVD ≤ 15<br>Preoperative OD/OS/Asymmetry<br>Postoperative OD/OS/Asymmetry  | 8,08/7,72/0,36<br>1,44/0,77/0,67                                       | 10,90/10,16/0,74<br>1,84/1,41/0,43                                      |
| DVD > 15 PD<br>Preoperative OD/OS/Asymmetry<br>Postoperative OD/OS/Asymmetry                                     | 20/10/10<br>10/0/10  | 20/20/0<br>6/6/0  |
| Limitation of elevation in abduction   | 0  | Mild in 34 pts,<br>Moderate in 9  |
| Limitation of elevation in straight up-gaze  | 0  | 8   |
| AES  | 0  | 2   |



## References

1. Wilson ME, Saunders RP (2009) Dissociated Deviations, Pediatric Ophthalmology. Current thoughts and a practical guide, Springer-Verlag Berlin Heidelberg, USA, pp. 153-161.
2. Brodsky MC (1999) DVD remains a moving target!. JAAPOS 3(6): 325-327.
3. Guyton DL (2000) Dissociated vertical deviation: etiology, mechanism and associated phenomena. Costenbader lectures. JAAPOS 4(3): 131-144.
4. Stager DR, Weakley DR, Stager D (1992) Anterior transposition of the inferior oblique. Anatomic assessment of the neurovascular bundle. Arch Ophthalmol 110(3): 360-362.
5. Santiago AP, Rosenbaum AL (1999) Dissociated vertical deviation. In: Rosenbaum AL & Santiago AP (Eds.), Clinical Strabismus Management. (1<sup>st</sup> edn), WB Saunders Company, Philadelphia, USA, pp. 237-247.
6. Guemes A, Wright KW (1998) Effect of graded anterior transposition of the inferior oblique muscle on versions and vertical deviation in primary position. JAAPOS 2(4): 201-206.
7. Balci YG, Ozkan S (2007) Transaction of the 31<sup>st</sup> ESA Meeting.
8. Gamio S (2011) Second surgery in DVD. JAAPOS 15(1): 18-19.
9. Mims JL, Wood RC (1999) Antielevation syndrome after bilateral anterior transposition of the inferior oblique muscles: Incidence and prevention. JAAPOS 3(6): 333-336.
10. Kushner BJ (2001) Torsion as a contributing cause of the antielevation syndrom. J AAPOS 5(3): 172-177.
11. Ellis FJ, Guyton DL (1998) Mechanism of action of the inferior oblique following anterior transposition. Ophthalmology 105: 544-551.
12. Quinn AG, Kraft SP, Day C, Taylor RS, Levin AV (2000) A prospective evaluation of anterior transposition of the inferior oblique muscle, with and without Resection, in the treatment of dissociated vertical deviation. JAAPOS 4(6): 348-353.