

Hyperbaric oxygen therapy in an isolated cilioretinal artery occlusion: a case report

Abstract

A 27-year-old female presented to the eye clinic with sudden vision loss in the right eye with onset of 4 hours prior to presentation. On ophthalmic examination, visual acuity was 0.05 in the right eye and 1.0 in the left eye. The anterior segment examination was normal and intraocular pressure was 14 mmHg in both eyes. Dilated fundus examination of the right eye showed an area of retinal ischemia with whitish edges in macular region. The patient was diagnosed as right isolated cilioretinal artery occlusion and underwent twenty sessions of hyperbaric oxygen therapy (120 minutes, 2 ATA). When she returned for follow-up evaluation on the 20th day the vision had improved to 10/10 in the right eye and there was a significant decrease in the previously observed retinal edema.

Keywords: hyperbaric oxygen therapy, cilioretinal artery occlusion

Volume 2 Issue 2 - 2015

Handan Akil,¹ Soner Keskin,² Mehmet Numan ALP³

¹Nevsehir State Hospital, Turkey

²Aydin State Hospital, Turkey

³Ankara Numune Training and Research Hospital, Turkey

Correspondence: Handan Akil, Nevsehir State Hospital, Nevsehir Devlet Hastanesi, Nevsehir, Turkey, Tel +905305923479, Email handanakil84@gmail.com

Received: February 17, 2015 | **Published:** April 2, 2015

Abbreviations: HBOT, hyperbaric oxygen therapy; OCT, optical coherence tomography

Introduction

The arterial blood supply to the eye is provided by the ophthalmic artery, one of the branches of the internal carotid artery. The branches of the ophthalmic artery which meet the metabolic needs of the globe are central retinal artery, short and long posterior ciliaries, anterior ciliaries. The central retinal artery enters the globe through the optic nerve and supplies blood to the inner layers of the retina. The long posterior ciliary arteries supply blood to the cilioretinal artery, choroid and the outer layers of the retina. The anterior ciliary arteries and posterior ciliary arteries anastomose to form the major arterial circle of the iris.¹ The human retina has two separate circulations; the retinal circulation supplies the inner layers of the retina and the choroidal circulation supplies the outer layers.² The retinal artery occlusions mostly affect inner retinal layers because choroidal circulation supplies the majority of the oxygen to the outer layers of the retina, and only the inner layers of the retina are nourished by the retinal circulation. Cilioretinal artery is present in approximately 15%-30% of population. This artery supplies the macular region of the retina, which is responsible for central vision. Isolated cilioretinal artery occlusion is a rare clinical entity and represents only 3% of all the retinal artery occlusions. Treatment considerations in using hyperbaric oxygen as adjunctive therapy for retinal vascular occlusions are early institution of treatment. We report a patient with isolated cilioretinal artery occlusion who responded to hyperbaric oxygen therapy (HBOT) well.

Case

A 27-year-old female presented to the eye clinic with sudden vision loss in the right eye with onset of 4 hours prior to presentation. Past medical history was unremarkable. Her best corrected visual acuity was 0.05 in the right eye and 1.0 in the left eye with snellen chart. The anterior segment examination of the both eyes with slit lamp biomicroscopy was normal. Intraocular pressure was normal in both eyes. Dilated fundus examination of the right eye showed an area of retinal ischemia with whitish edges in the macular region (Figure 1) and the left eye was normal. Visual field testing was not relevant due to the reduced vision in the right eye. Fluorescein angiography of the

right eye showed delayed filling of the cilioretinal artery and masking of choroidal fluorescence because of the retinal edema. Fluorescein angiography was normal in the left eye. Optical coherence tomography (OCT) (Carl Zeiss Meditec Inc., Dublin, CA) revealed increase in thickness and hyper-reflectivity of the inner retinal layers in affected area and shadowing with decreased reflectivity of photoreceptor and retinal pigment epithelial layers, consistent with intracellular edema (Figure 2). After the diagnosis, the patient was treated with oral carbonic anhydrase inhibitors (acetazolamide 250mg tablet 1x2), intravenous hyperosmolar agent (300 cc mannitol) and topical antiglaucomatous medication (brimonidine/timolol combination).

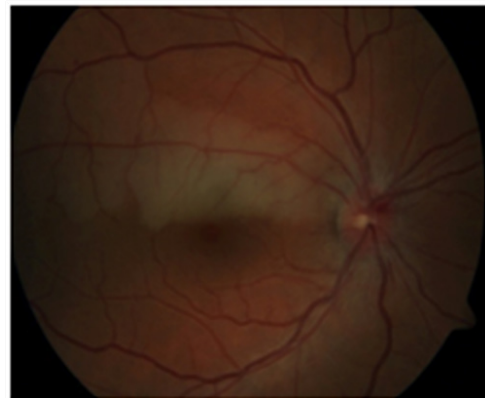


Figure 1 The color fundus photograph of the right eye that shows retinal ischemia with whitish edges.

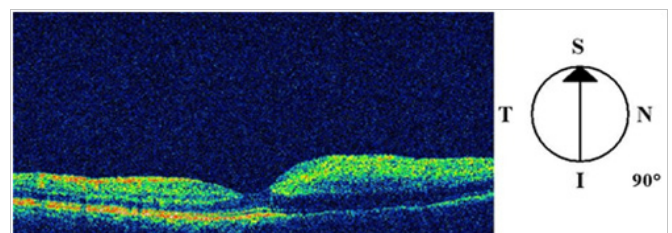


Figure 2 Optical coherence tomography of the right eye revealed increase in thickness and hyper-reflectivity of the inner retinal layers in affected area consistent with intracellular edema.

Ocular massage of the right eye was carried out for 15 minutes than the patient was referred to the HBOT center to be treated with HBOT at 2.0 ATA (atmosphere absolute) oxygen 120 minutes daily for 20 sessions. Patient was checked for any other disease which can cause vascular occlusion but only high blood homocystein; low vitamin B12 levels were found in laboratory tests and treatment was started. Twenty days after the initiation of the therapy visual acuity of the right eye improved to 1.0. Visual field test was interpreted as paracentral scotoma localized below the horizontal midline which is consistent with superior nerve fiber damage in the right eye (Figure 3). Three months after the initial visit, repeat fluorescein angiography showed remarkable improvement in fluorescein filling of the cilioretinal artery, which started almost at the same time as the choroidal flush (Figure 4). OCT demonstrated thinning of the neural sensory retina with normal foveal contour (Figure 5). Repeat perimetry showed a smaller paracentral scotoma compared to the defect on the 20th day of treatment (Figure 6).

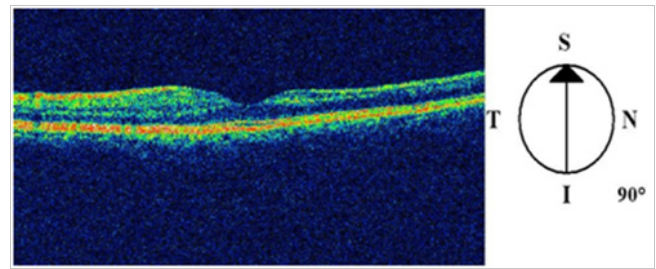


Figure 5 Three months after the initial visit, Optical coherence tomography demonstrated thinning of the neural sensory retina with normal foveal contour.

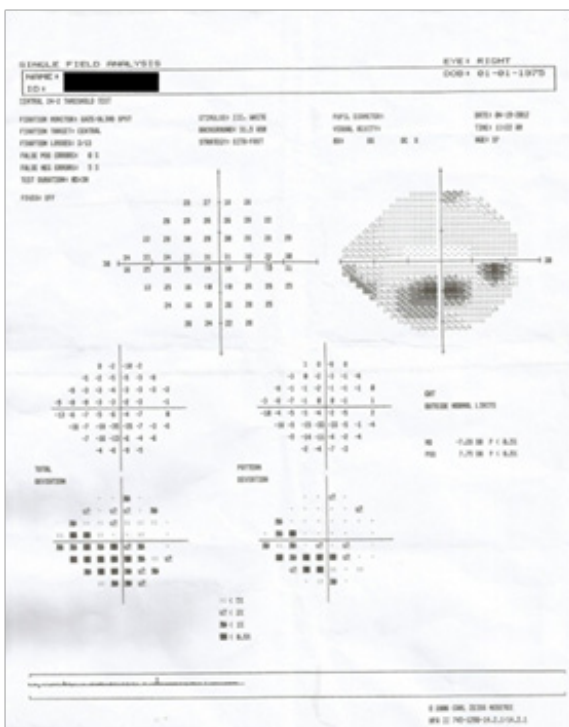


Figure 3 Visual field test was interpreted as paracentral scotoma localized below the horizontal midline which is consistent with superior nerve fiber damage in the right eye.

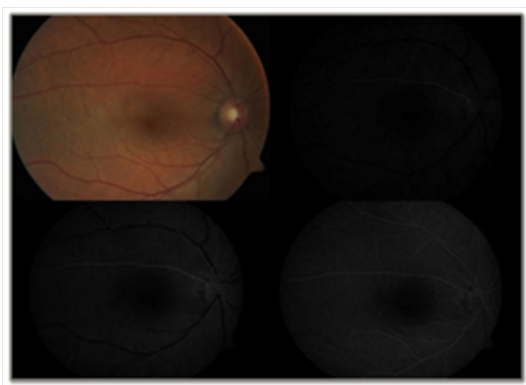


Figure 4 Three months after the initial visit, repeat fluorescein angiography showed remarkable improvement in fluorescein filling of the cilioretinal artery, which started almost at the same time as the choroidal flush.




Figure 6 Three months after the initial visit, visual field testing demonstrated a significant decrease in the size of the visual field defect.

Discussion

HBOT may be used as an adjuvant or major treatment modality in many ocular disorders, progress in this field needs understanding the effects of hyperoxia on the normal eye. According to theoretical models during systemic hyperoxia, oxygen could be supplied to the deeper regions of the retina by choroid. So under hyperbaric oxygenation, the calculations showed that choroid should meet needed oxygen to both inner and outer retinal layers.^{3,4} Many clinicians have been using different treatment choices to decrease intraocular pressure and produce vasodilatation for retinal artery occlusions with a main purpose of facilitating movement of the emboli if present. Most of these conventional treatments are found to be ineffective,⁵ but HBOT may be useful reversing vision loss in at least some cases of retinal artery occlusion. So we treated our patient with HBOT besides conventional treatment regimens. Hertzog et al.⁶ studied the importance of the HBOT timing in central retinal artery occlusion cases. They reported that preserving visual function may be possible if HBOT applied within 8 hours from the onset Henderson et al.⁷ Evaluated the prognosis of 16 patients treated with HBOT for central retinal artery occlusion. The patients who had been late for the treatment more than 24 hours, showed no improvement.

Weiss et al.⁸ reported five patients with symptoms secondary to branch and cilioretinal artery occlusion who were treated with HBOT. All patients responded to HBOT well without any complication. They concluded that HBOT may be more effective treatment for patients with branch retinal and cilioretinal artery occlusion because of the localized ischemic lesion compared to the central retinal artery occlusion. Takeuchi et al.⁹ Reported a patient with central retinal artery occlusion occurring after a long surgical procedure. HBOT and systemic vasodilator treatment initiated after the diagnosis and the therapy resulted in improvement of the affected eye.

The visual prognosis associated with retinal artery occlusions remains poor and current acute managements have limited and unproven benefit to improve the vision.^{10,11} Many studies reported a variety of treatment attempts such as ocular massage, acetylsalicylic acid, beta-blocker, carbogen (95% oxygen and 5% carbon dioxide), topical timolol maleate, acetazolamide and anterior chamber paracentesis but these have not been found as a safe and efficacious option for this visually disabling condition.^{12,13} Our patient responded to the HBOT treatment well. The improvement may also be related with the early timing of the treatment, the young age, and absence of the any precipitating factor. HBOT is a relatively safe, easily administered treatment which may produce an improvement in vision.⁶⁻⁹ Further study is required to define the value of this therapy in the treatment of retinal artery occlusions.

Acknowledgments

None.

Conflicts of interest

Author declares that there is no conflict of interest.

References

1. Cibis GW, Beaver HA, Johns K. *Basic and Clinical Science Course: Fundamentals and Principles of Ophthalmology*. USA: American Academy of Ophthalmology, San Francisco; 2006. p. 38–40.
2. Regillo D, Chang TS, Johnson MW. *Basic and Clinical Science Course: Retina and Vitreous*. USA: American Academy of Ophthalmology, San Francisco; 2007.
3. Piantadosi CA. Physiology of hyperbaric hyperoxia. *Respir Care Clin N Am*. 1999;5(1):7–19.
4. Dollery CT, Bulpitt CJ, Kohner EM. Oxygen supply to the retina from the retinal and choroidal circulations at normal and increased arterial oxygen tensions. *Invest Ophthalmol*. 1969;8(6):588–594.
5. Neubauer AS, Mueller AJ, Schriever S, et al. Minimally invasive therapy for clinically complete central retinal artery occlusion--results and meta-analysis of literature. *Klin Monatsbl Augenheilkd*. 2000;217(1):30–36.
6. Hertzog LM, Meyer GW, Carson S, et al. Central retinal artery occlusion treated with hyperbaric oxygen. *J Hyperbaric Medicine*. 1992;7:33–42.
7. Henderson LT, Slade JB, Cianci PE. Central retinal artery occlusion and hyperbaric oxygen therapy. *Undersea Hyperb Med*. 2004;31:309.
8. Weiss JN. Hyperbaric oxygen treatment of retinal artery occlusion. *Undersea Hyperb Med*. 2010;37(3):167–172.
9. Takeuchi M, Morita K, Nakatsuka H, et al. A case of central retinal artery occlusion after anterior posterior fusion of the lumbar spine. *Masui*. 2001;50(8):899–901.
10. Schmidt D, Schumacher M, Wakhloo AK. Microcatheter urokinase infusion in central retinal artery occlusion. *Am J Ophthalmol*. 1992;113(4):429–434.
11. Duker JS, Sivalingam A, Brown GC, et al. A prospective study of acute central retinal artery obstruction: the incidence of secondary ocular neovascularization. *Arch Ophthalmol*. 1991;109(3):339–342.
12. Rumelt S, Dorenboim Y, Rehany U. Aggressive systematic treatment for central retinal artery occlusion. *Am J Ophthalmol*. 1999;128(6):733–738.
13. Beatty S, Au Eong KG. Acute occlusion of the retinal arteries: current concepts and recent advances in diagnosis and management. *J Accid Emerg Med*. 2000;17(15):324–329.